

Speciālās histoloģijas kurss


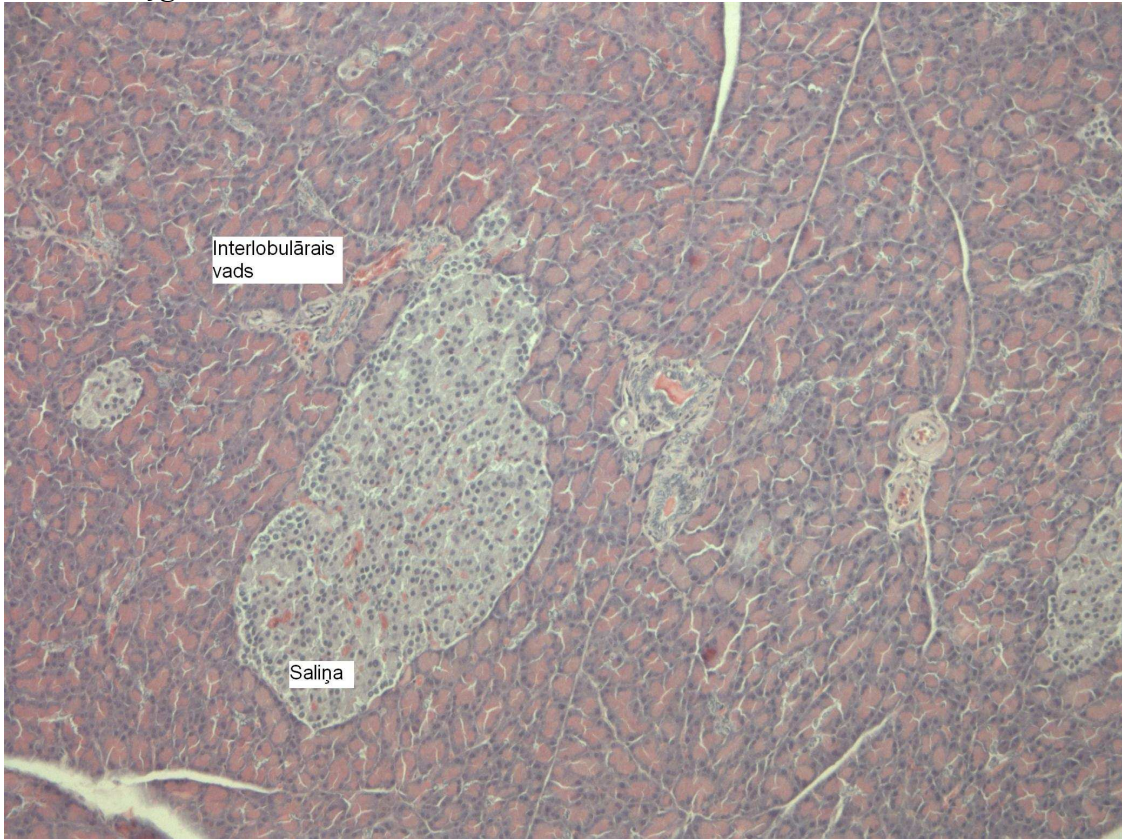
Laboratorijas darbos izmantoto preparātu attēlu atlants

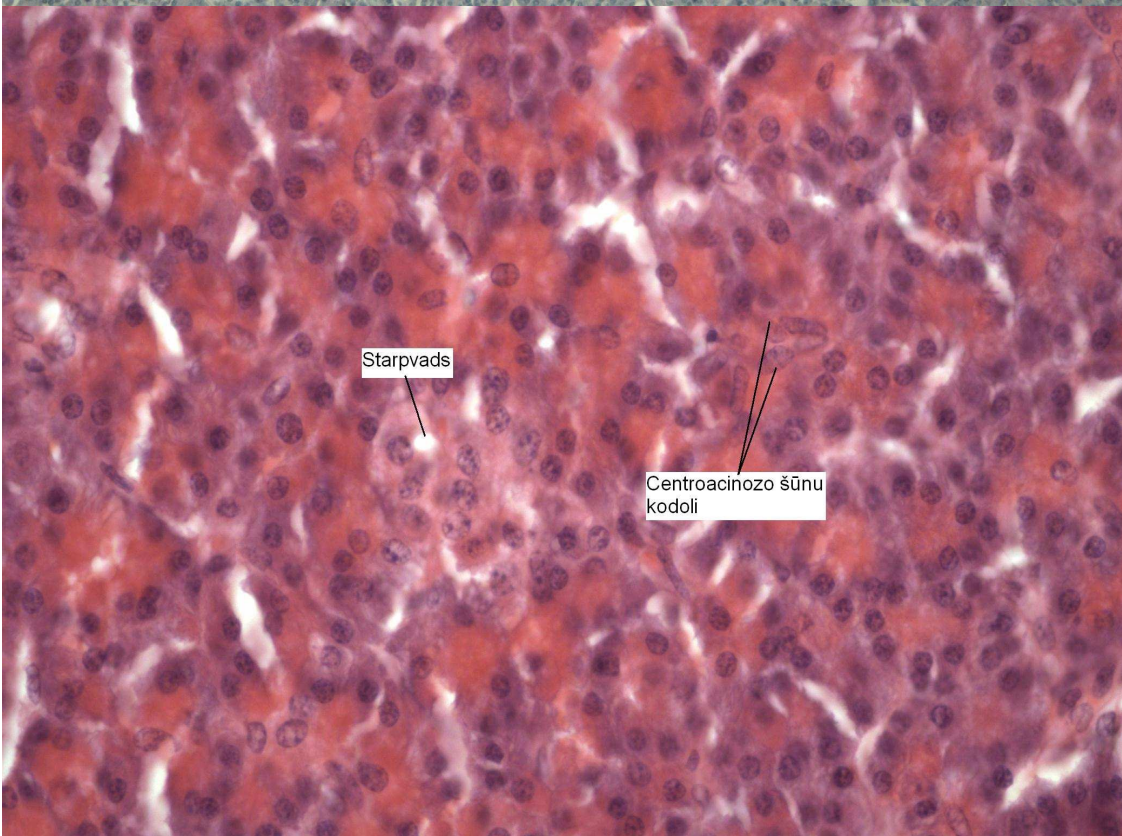
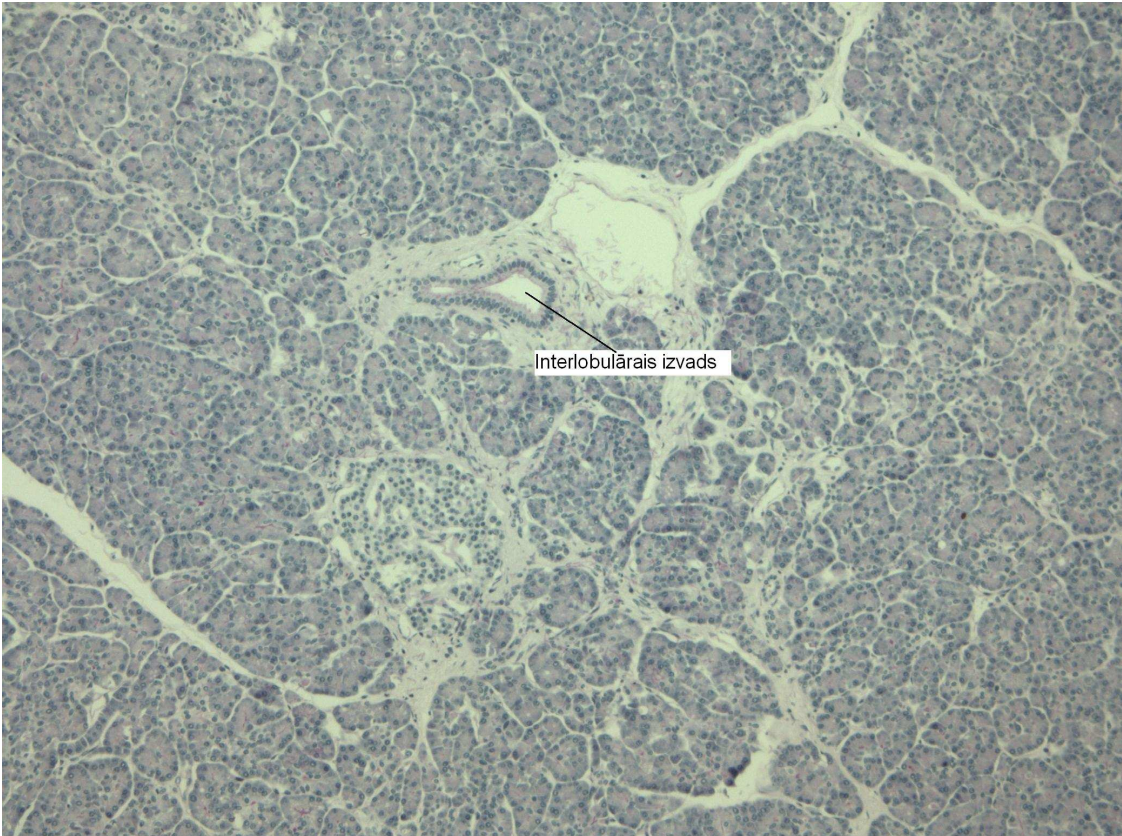
Rīga 2011.

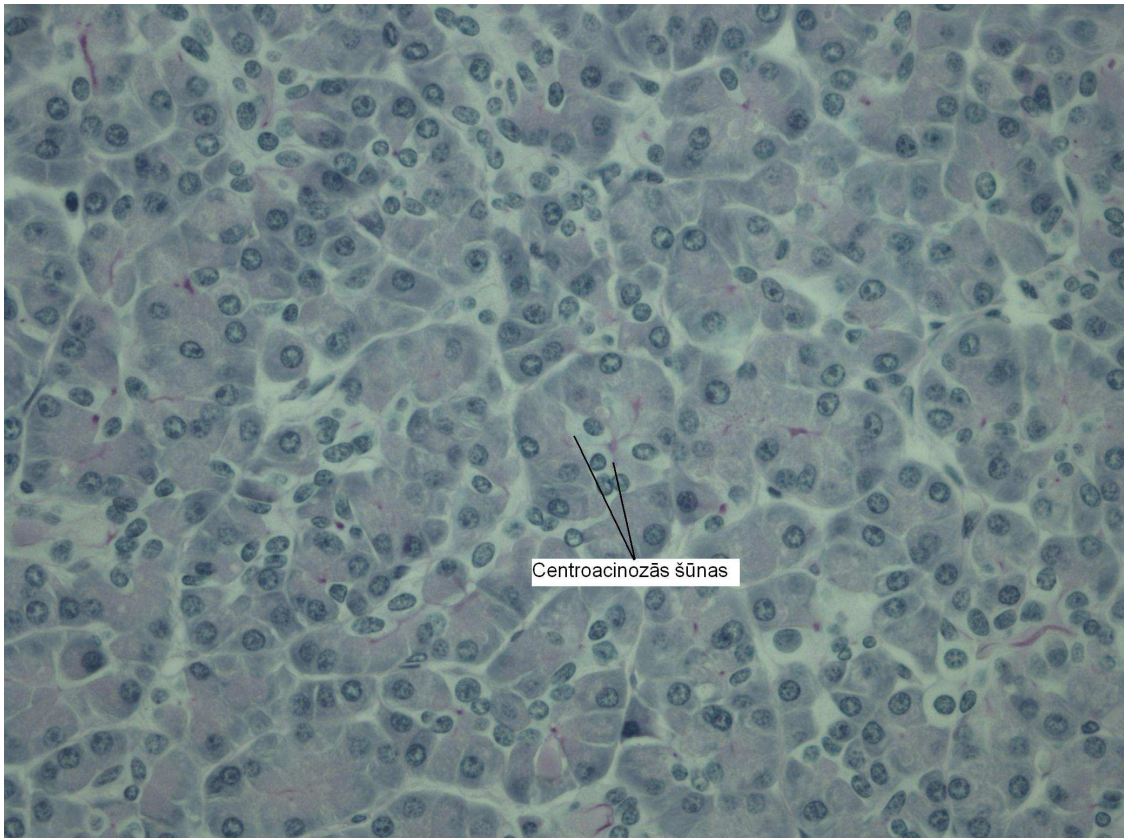
4. nodarbība

Barības vads. Kuņģis. Tievā zarna. Tārpveida piedēklis. Resnā zarna.

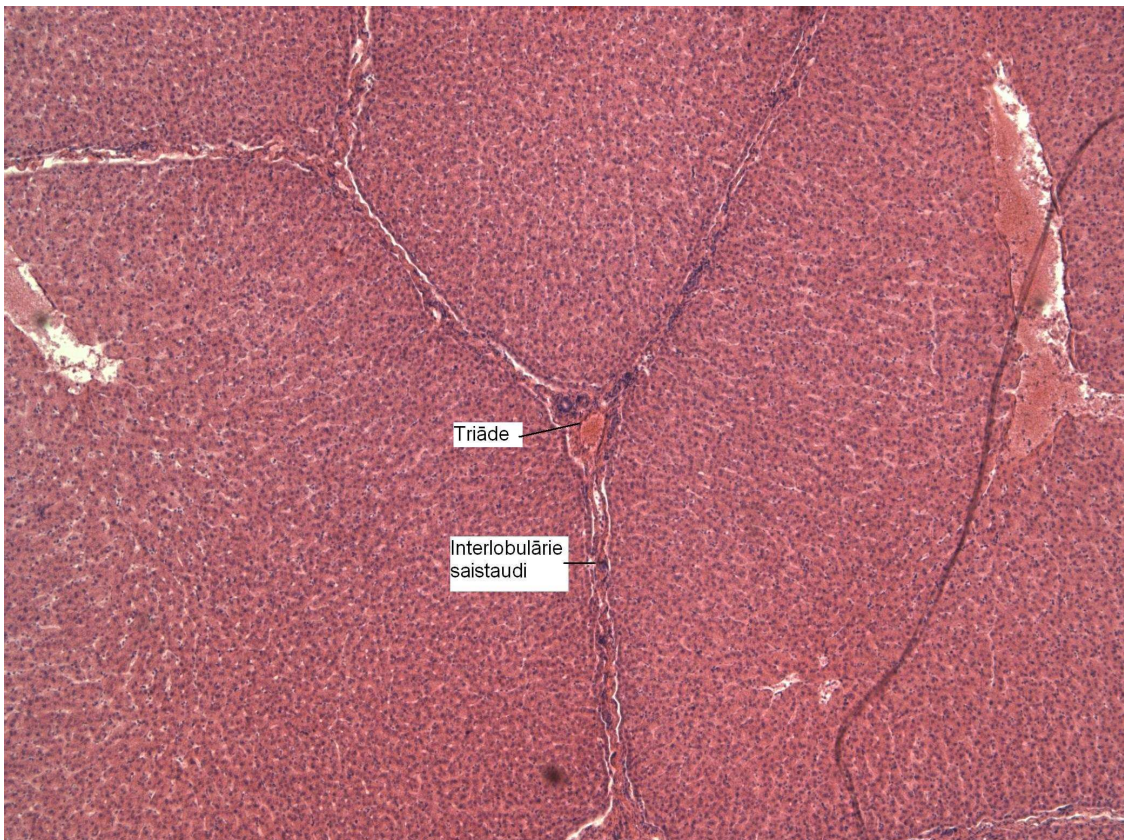
1. – Aizkuņģa dziedzeris

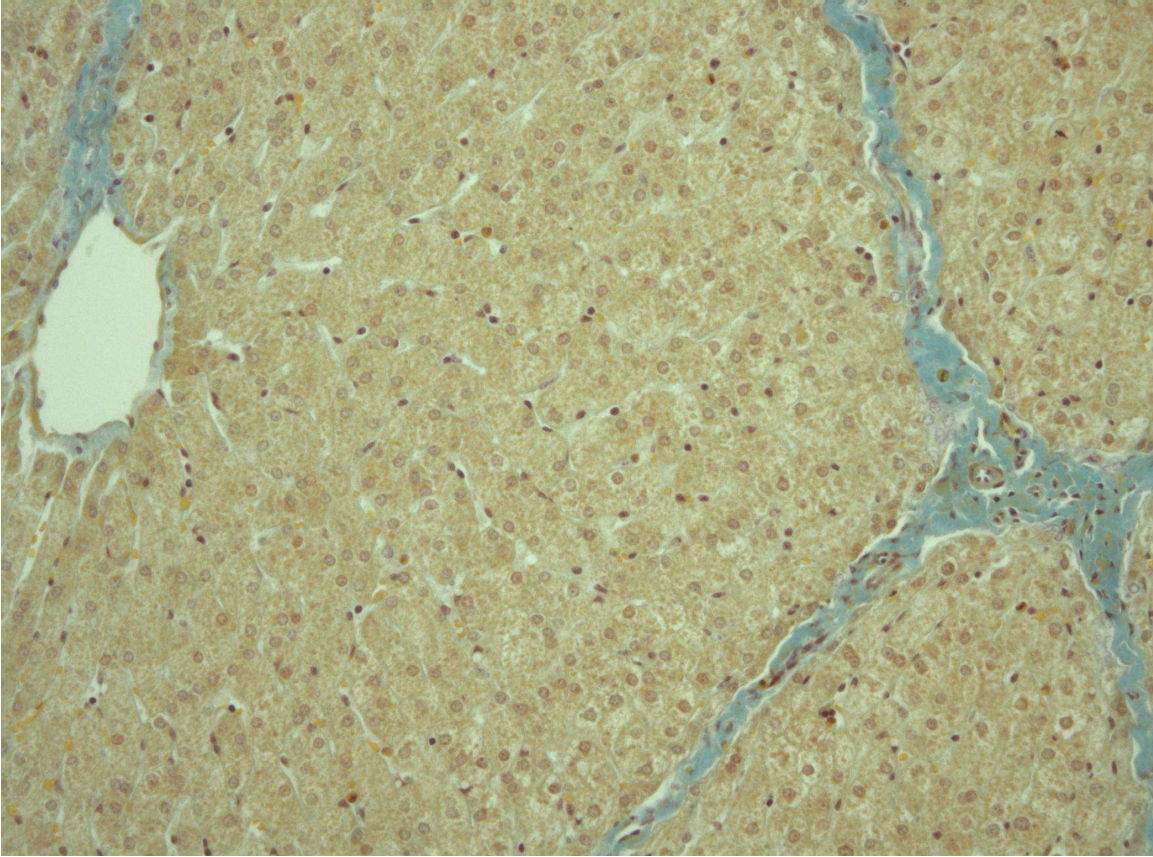
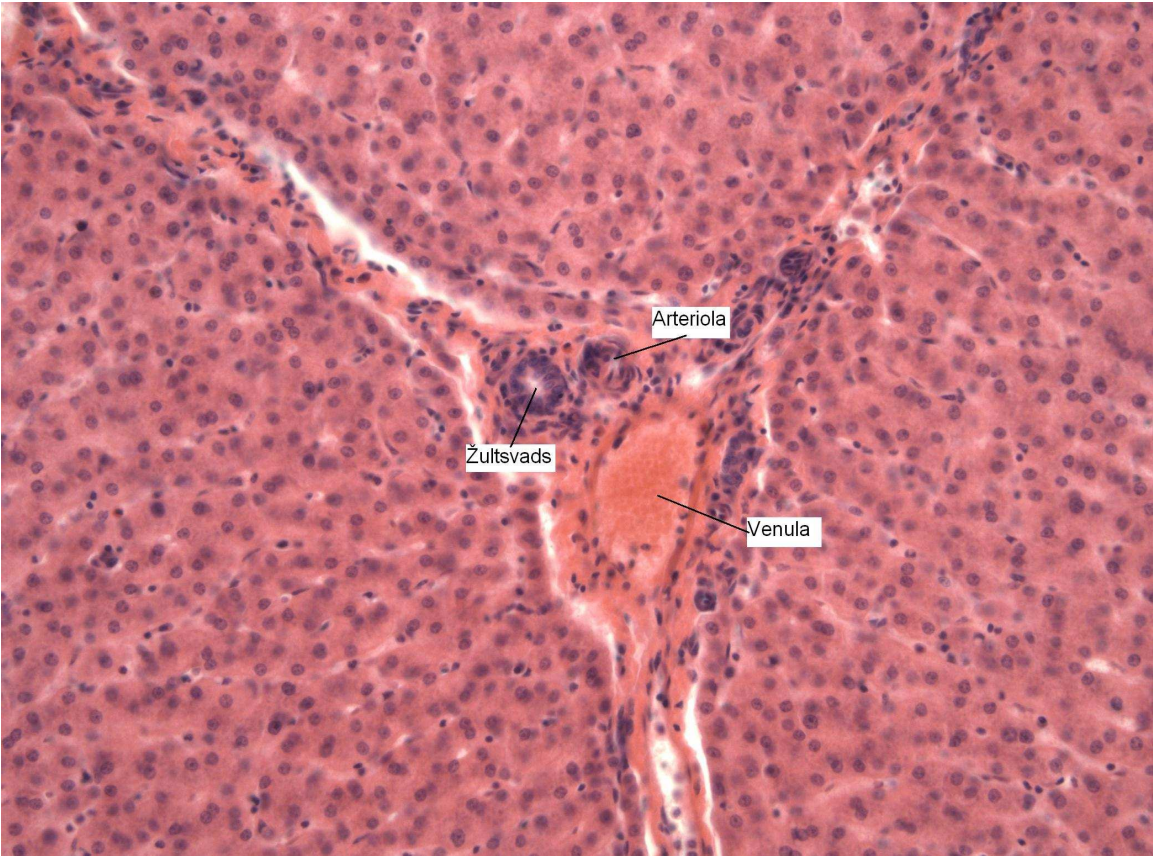



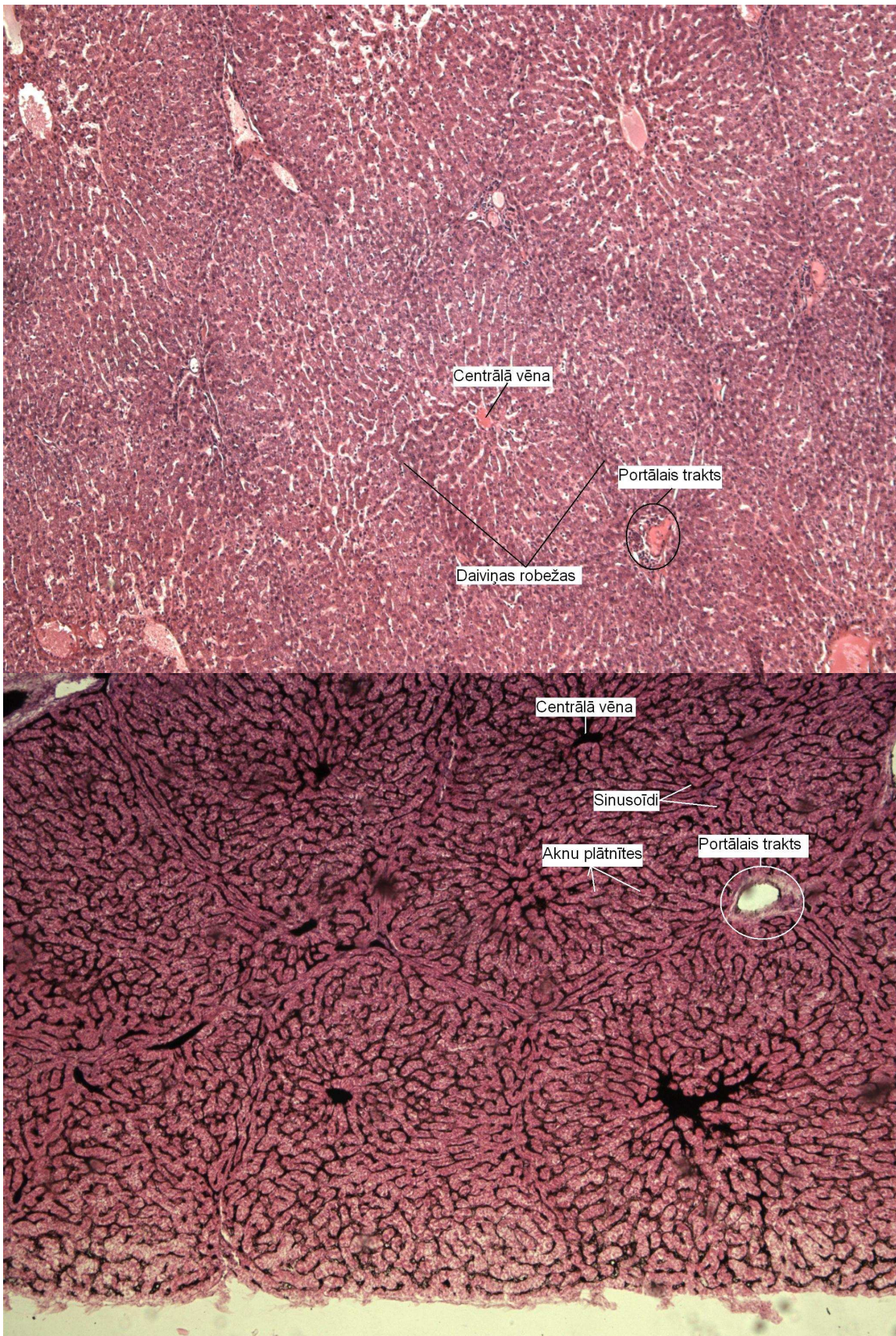


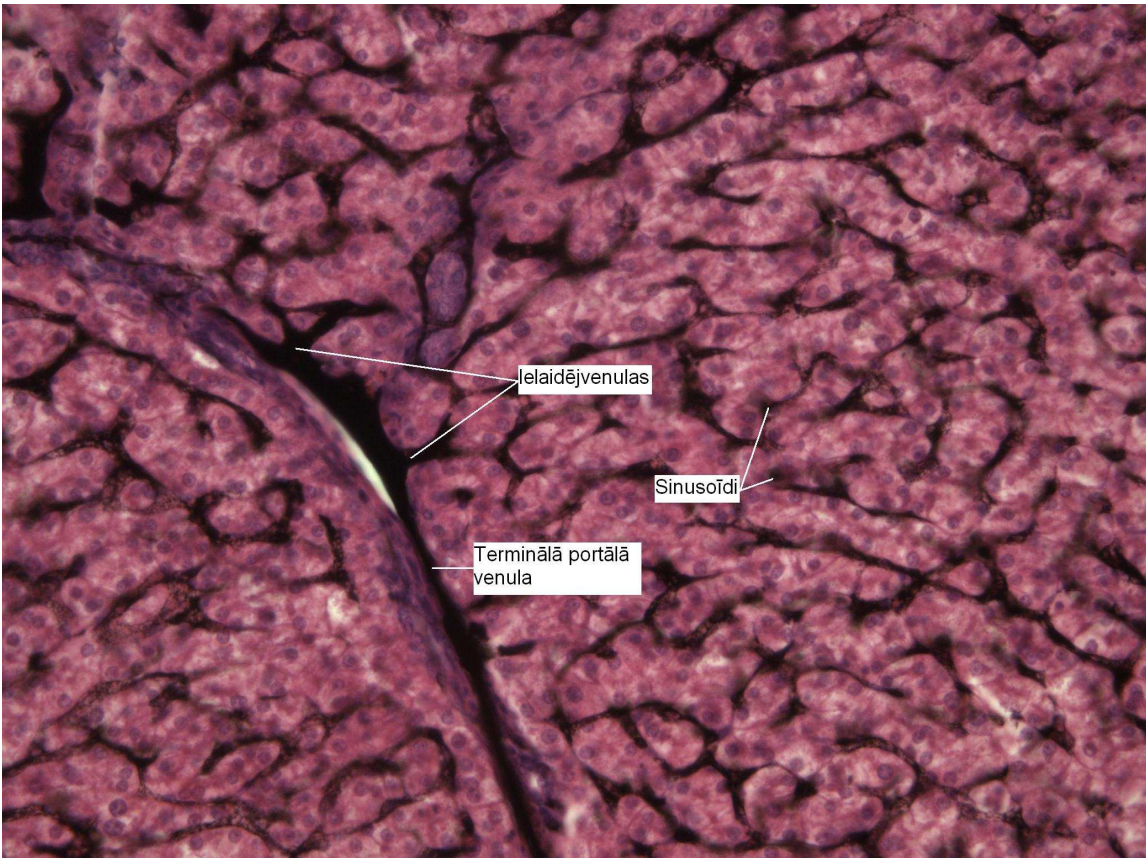
2. – Cūkas aknas



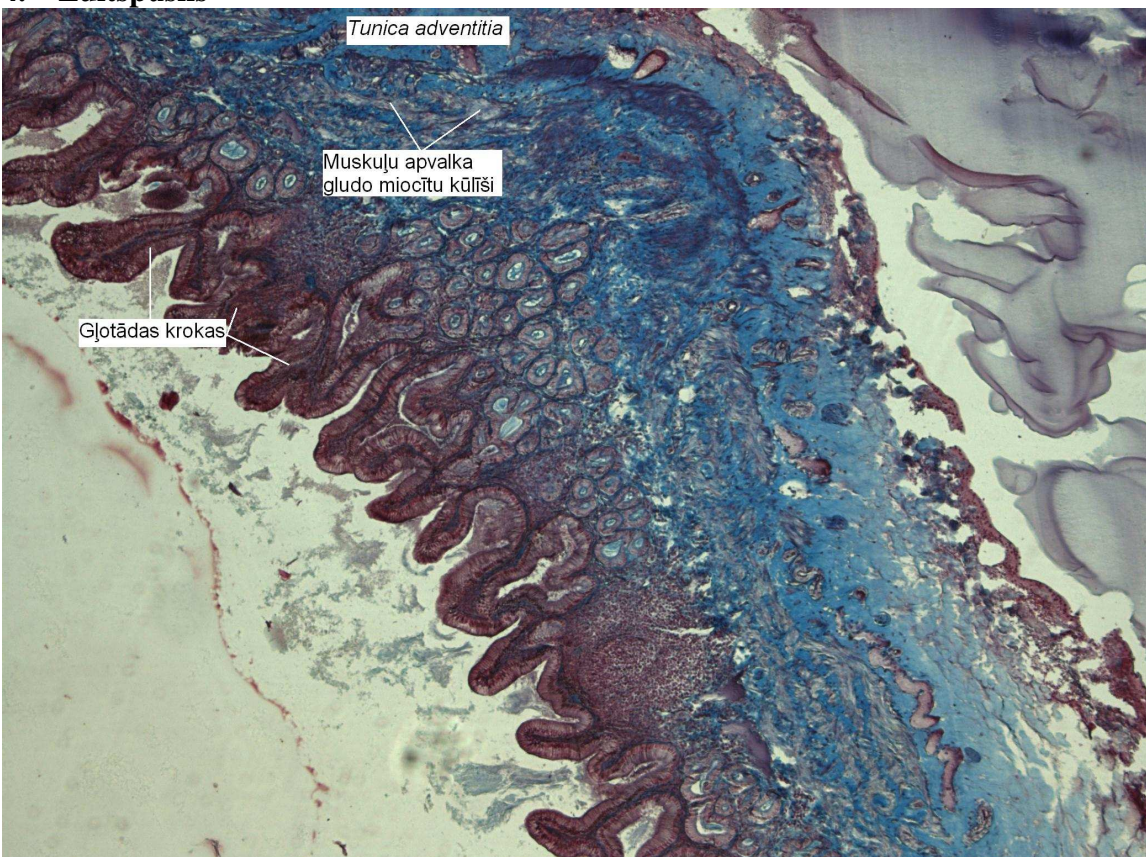


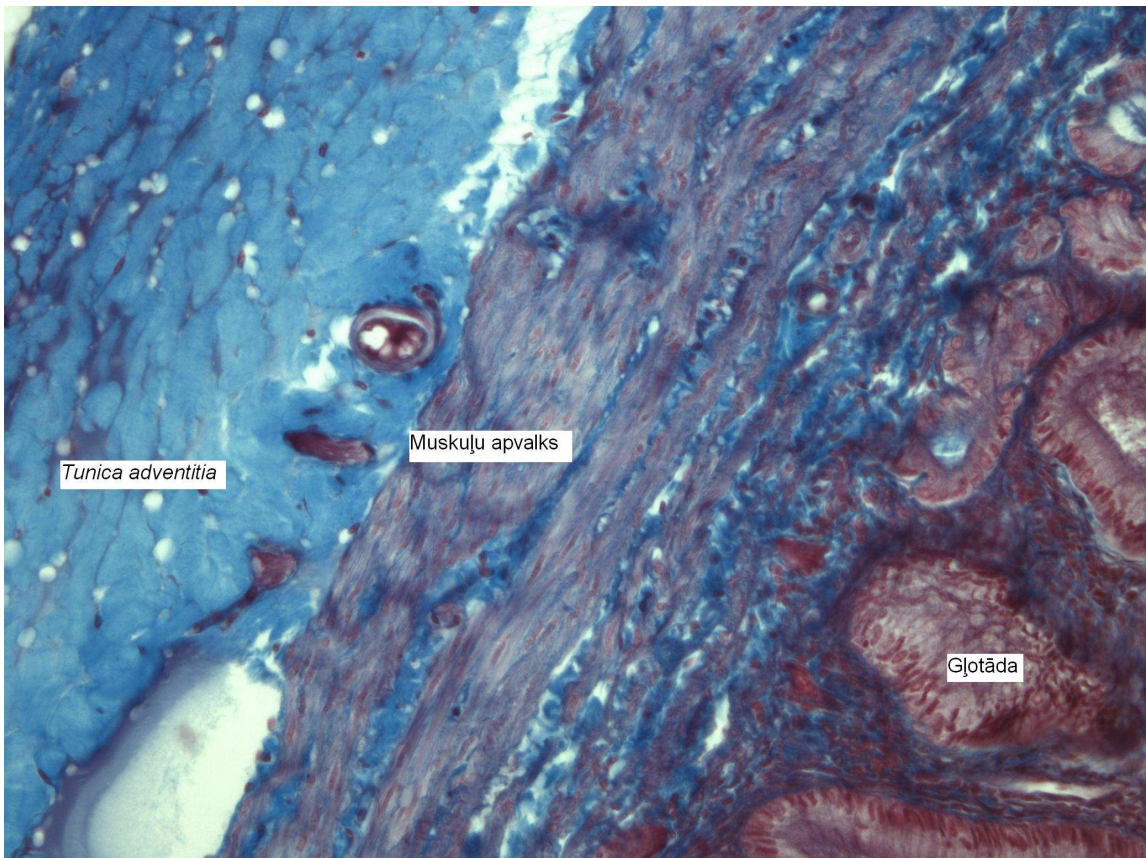
3. – Cilvēka aknas





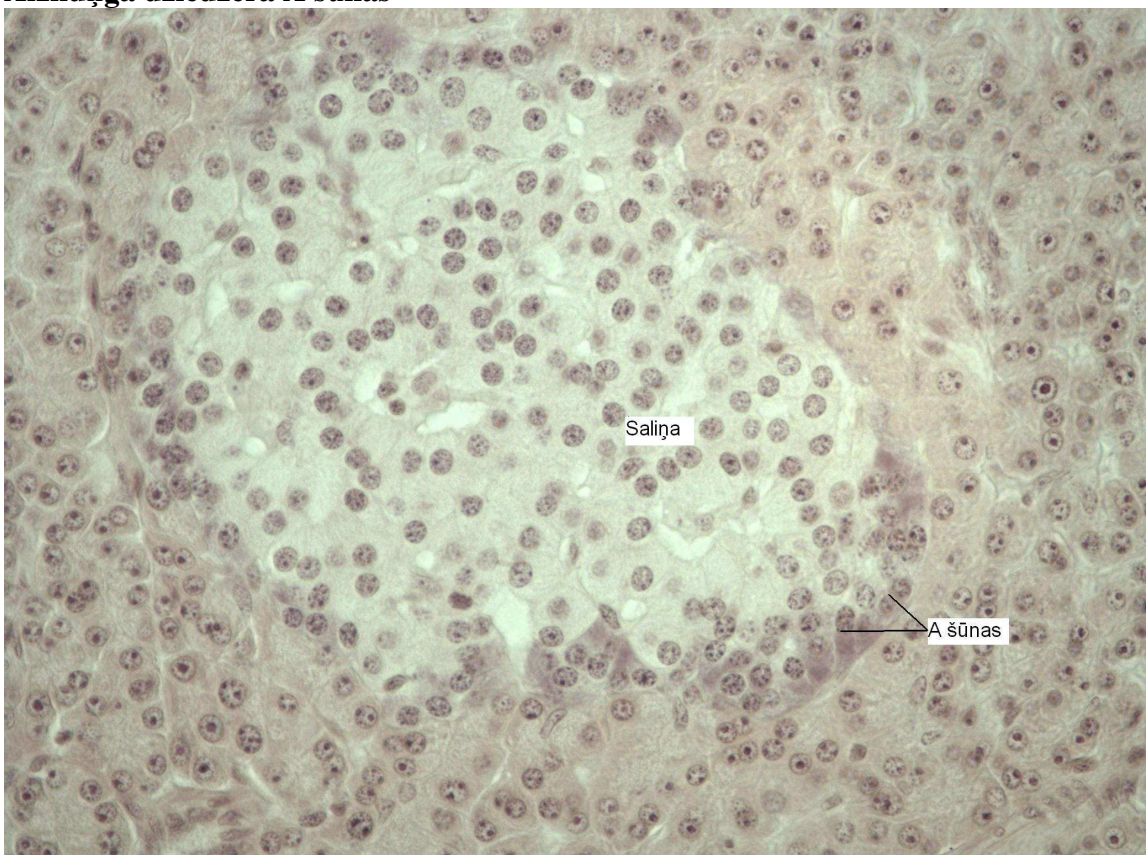
4. – Žultspūslis



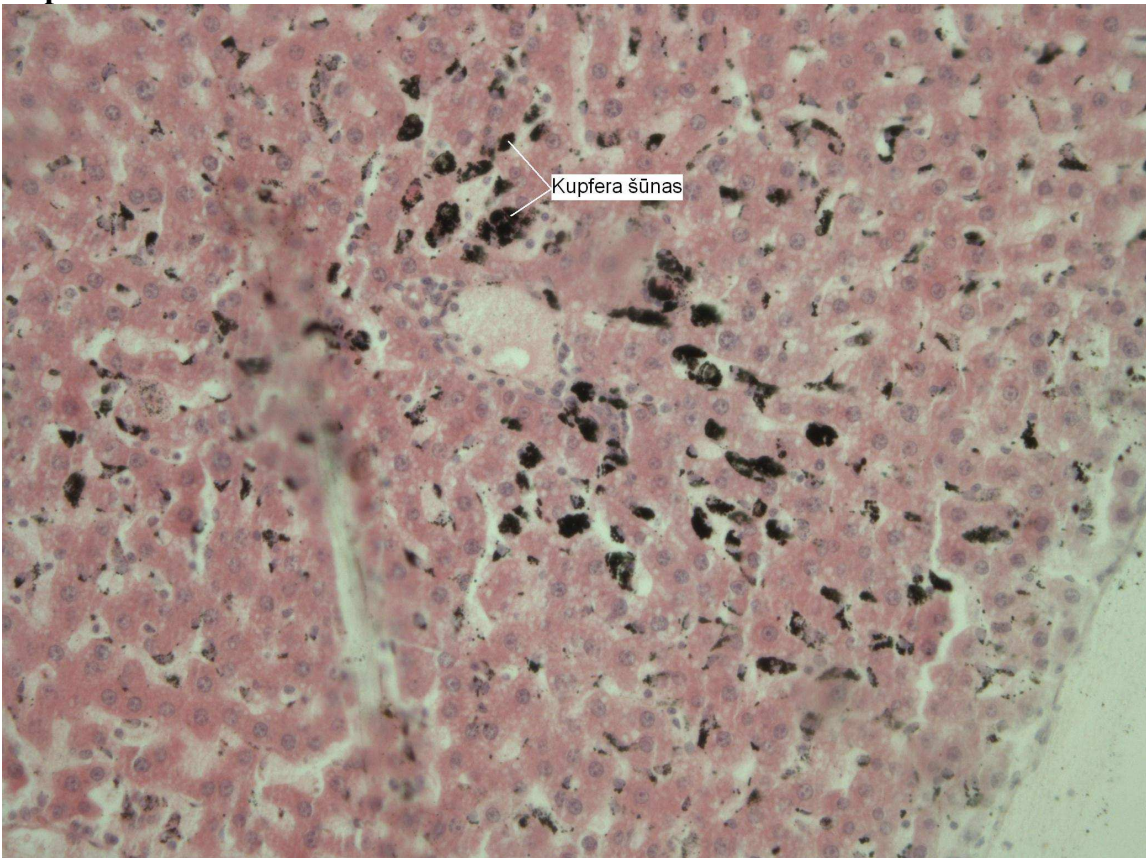


Demonstrējamie preparāti: aizkuņģa dziedzera A šūnas, kupfera šūnas, žults kanāliņi aknās, zīmogēnās granulas.

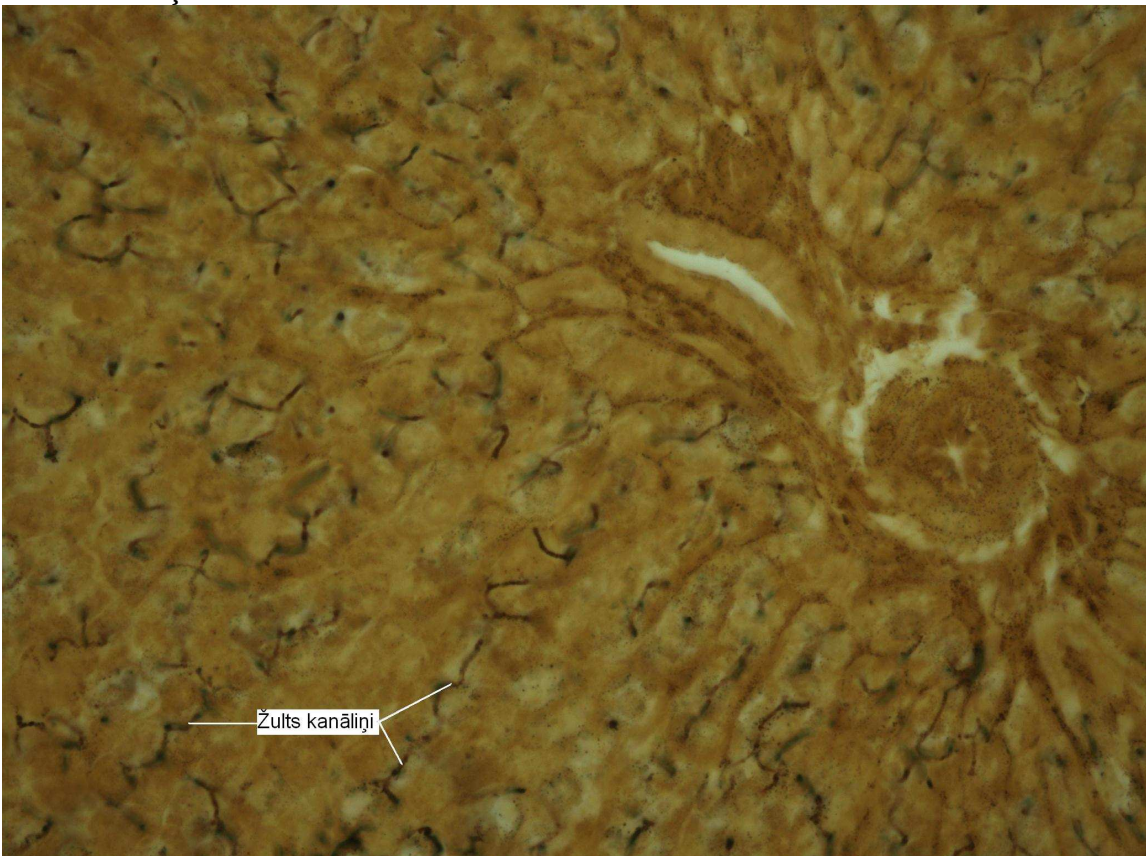
Aizkuņģa dziedzera A šūnas



Kupfera šūnas



Žults kanāliņi aknās



Zimogēnās granulas

