

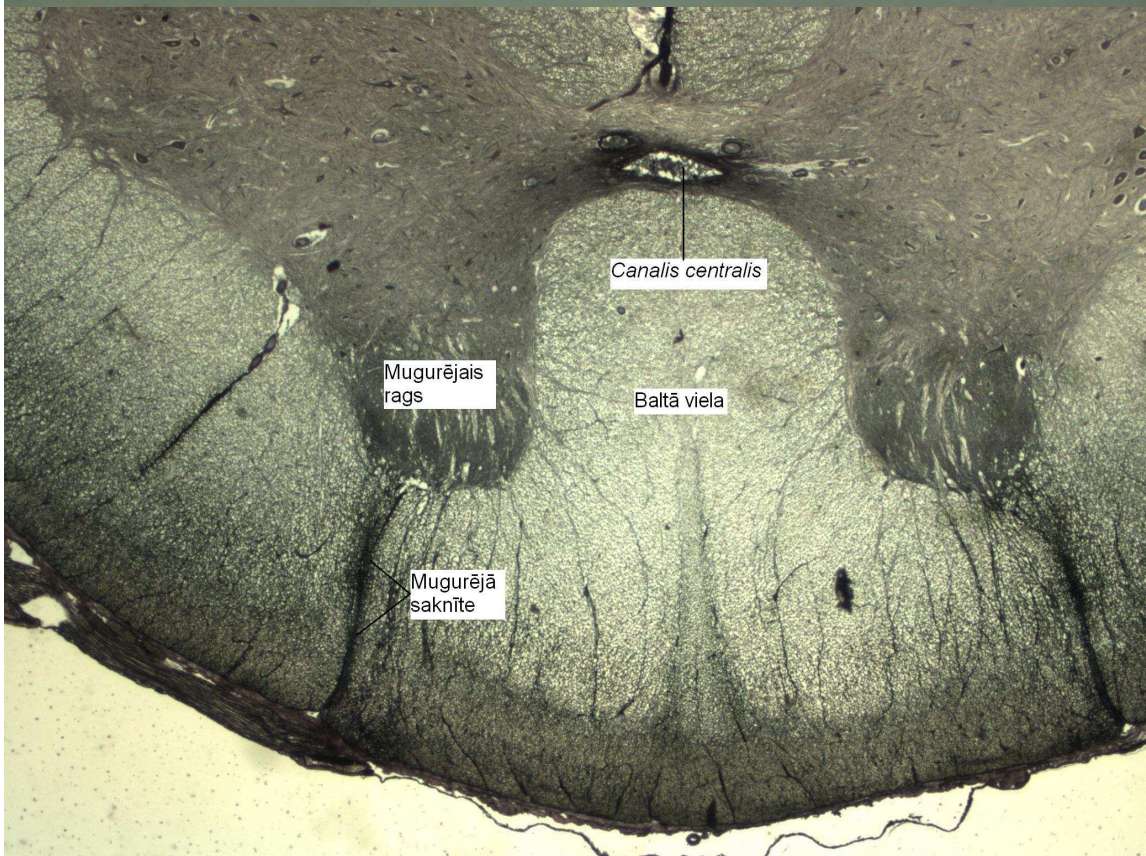
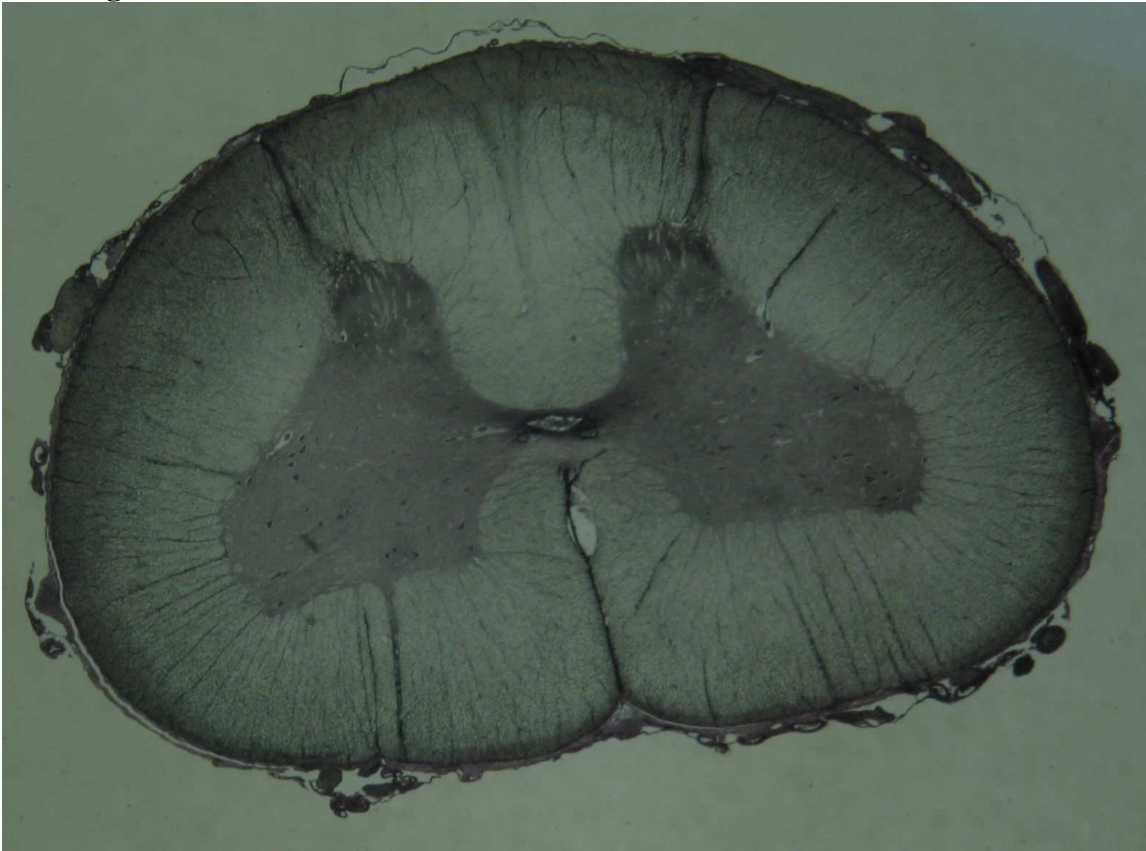
Speciālās histoloģijas kurss

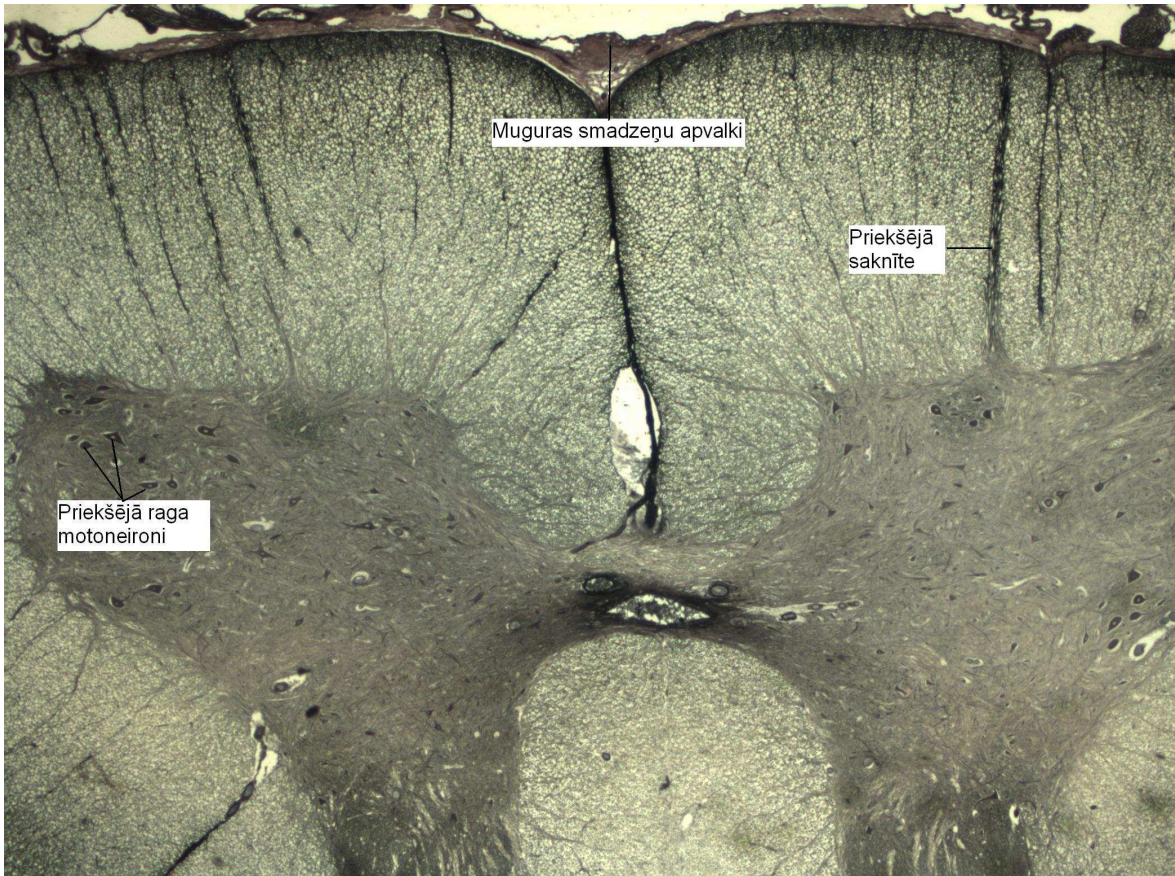
Laboratorijas darbos izmantoto preparātu attēlu atlants

Rīga 2011.

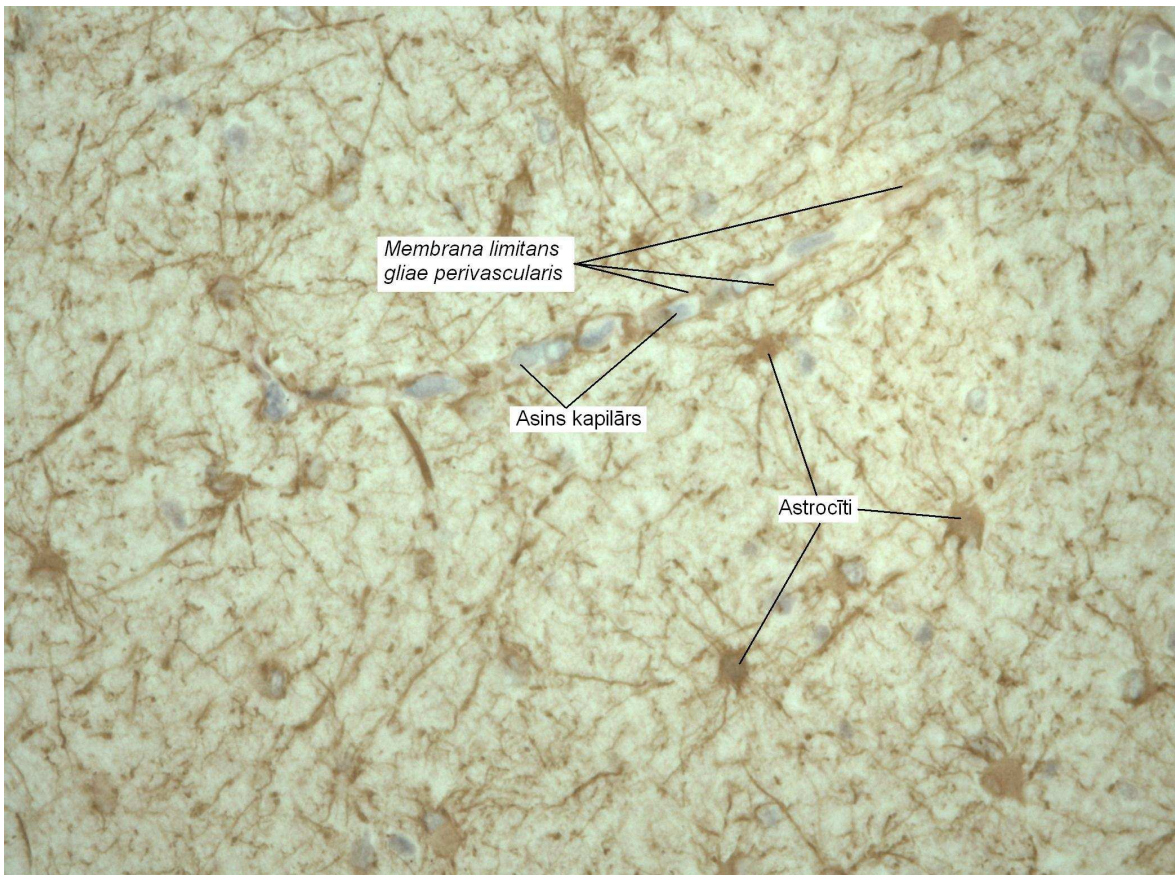
8. nodarbība Centrālā nervu sistēma.

1. – Muguras smadzenes.

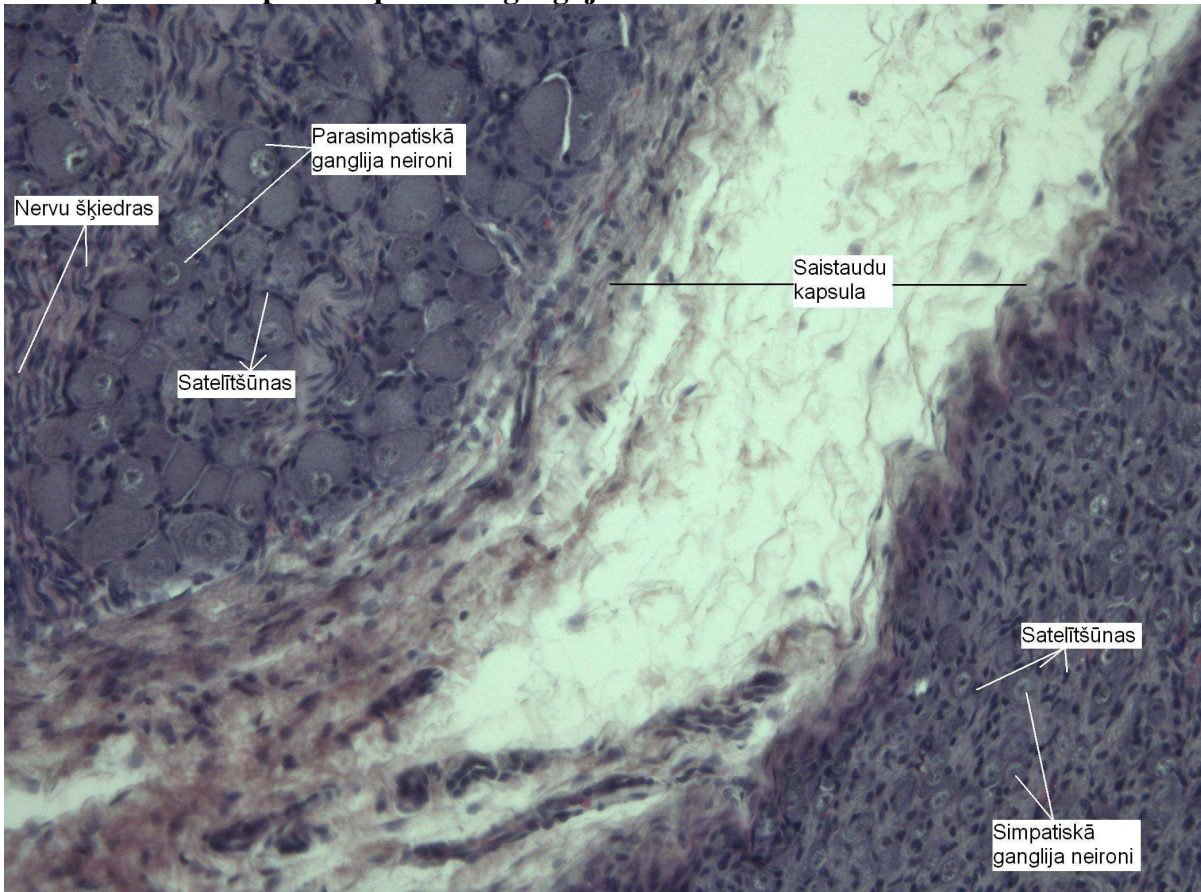




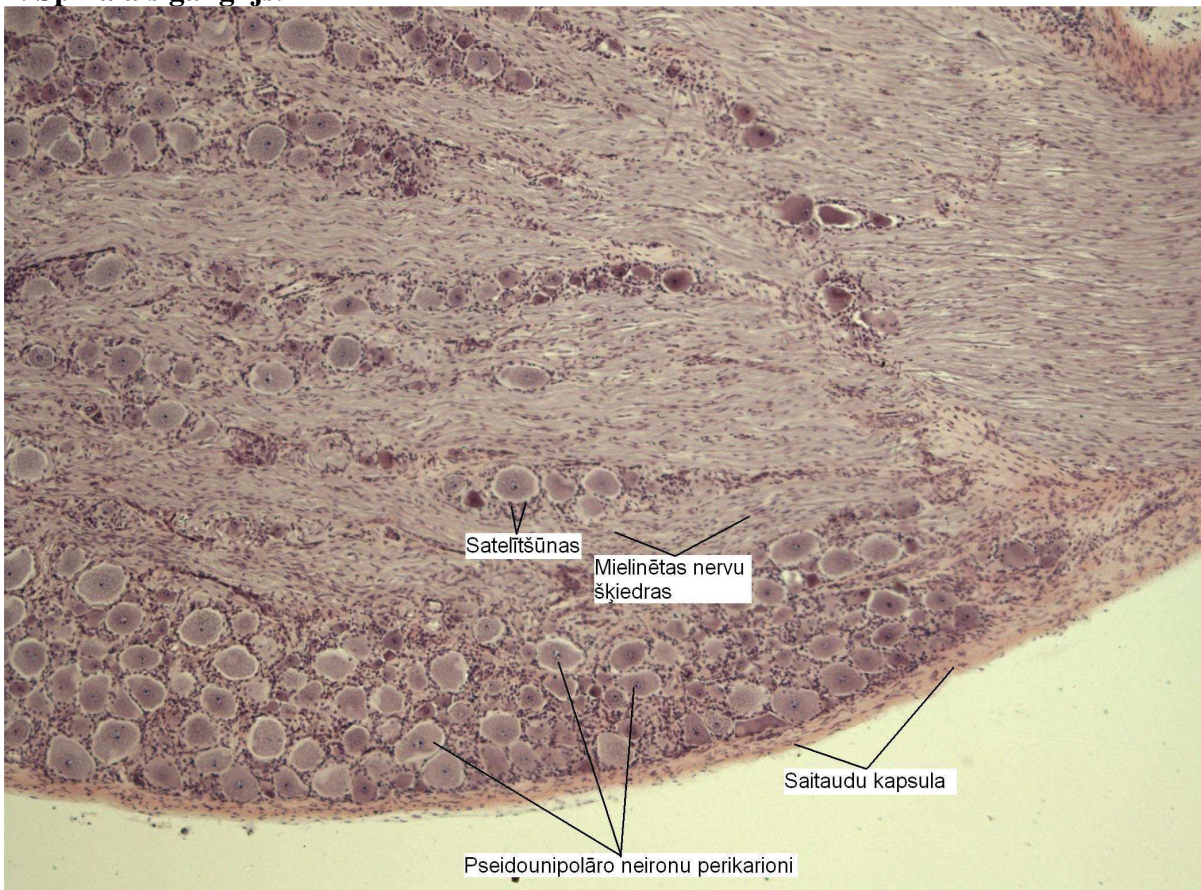
2. Astrocīti



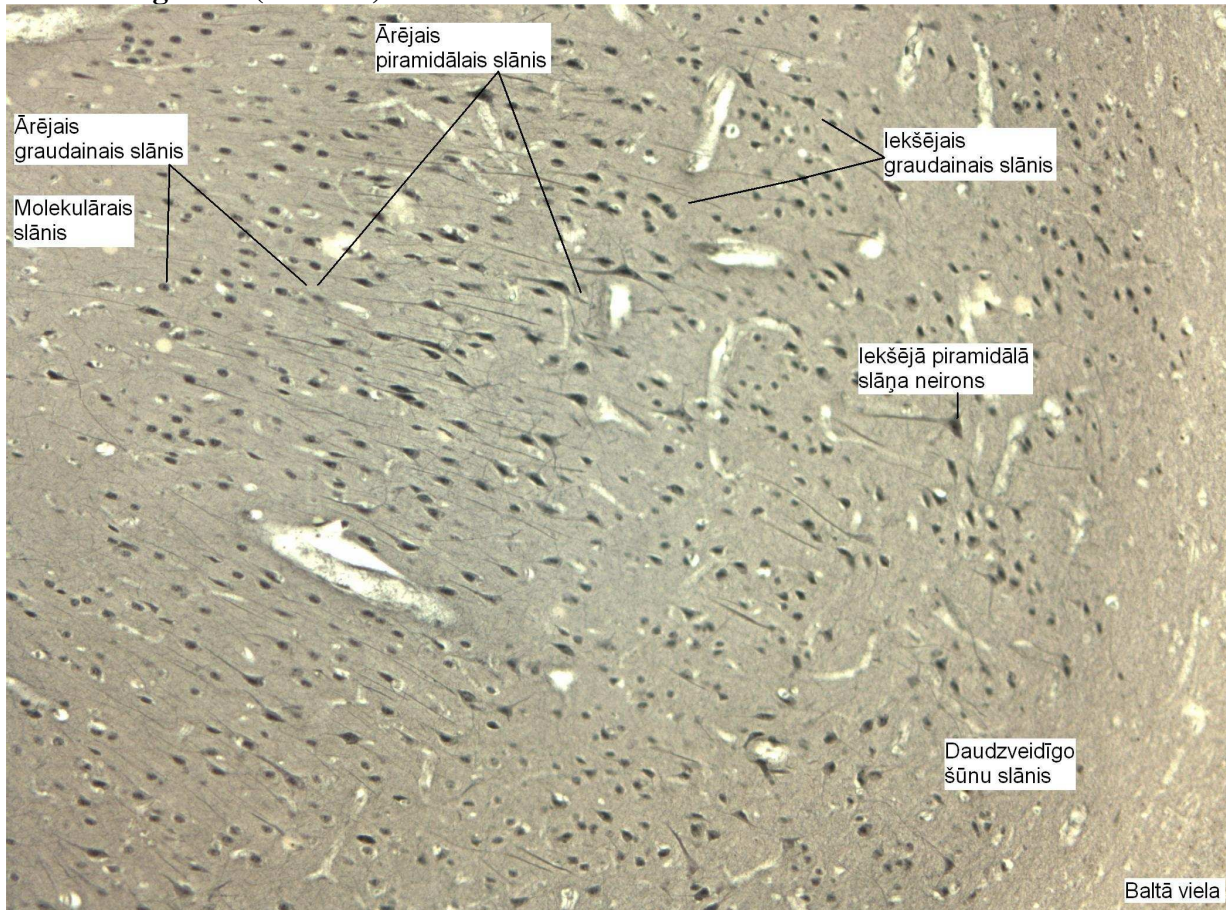
3. Simpatiskais un parasimpatiskais ganglijs.



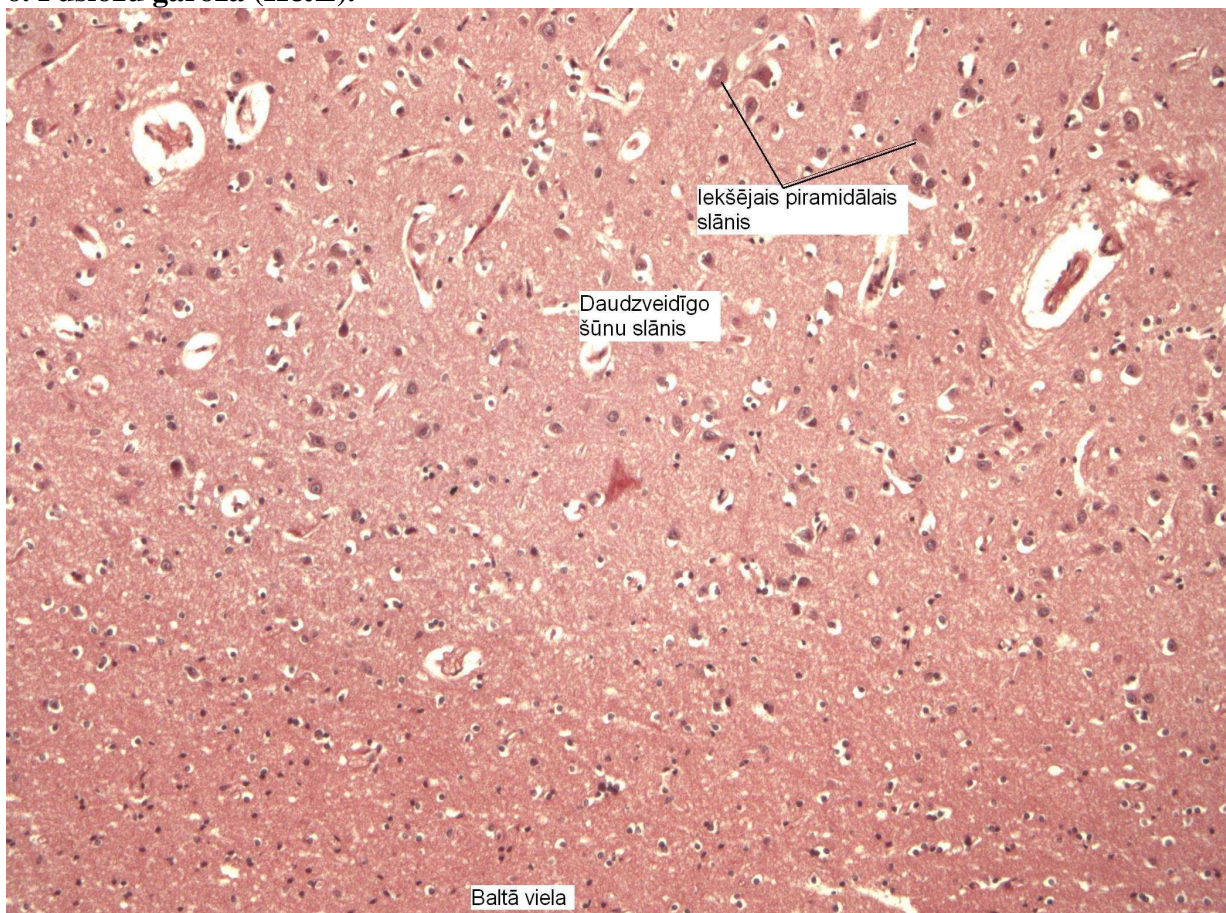
4. Spinālais ganglijs.

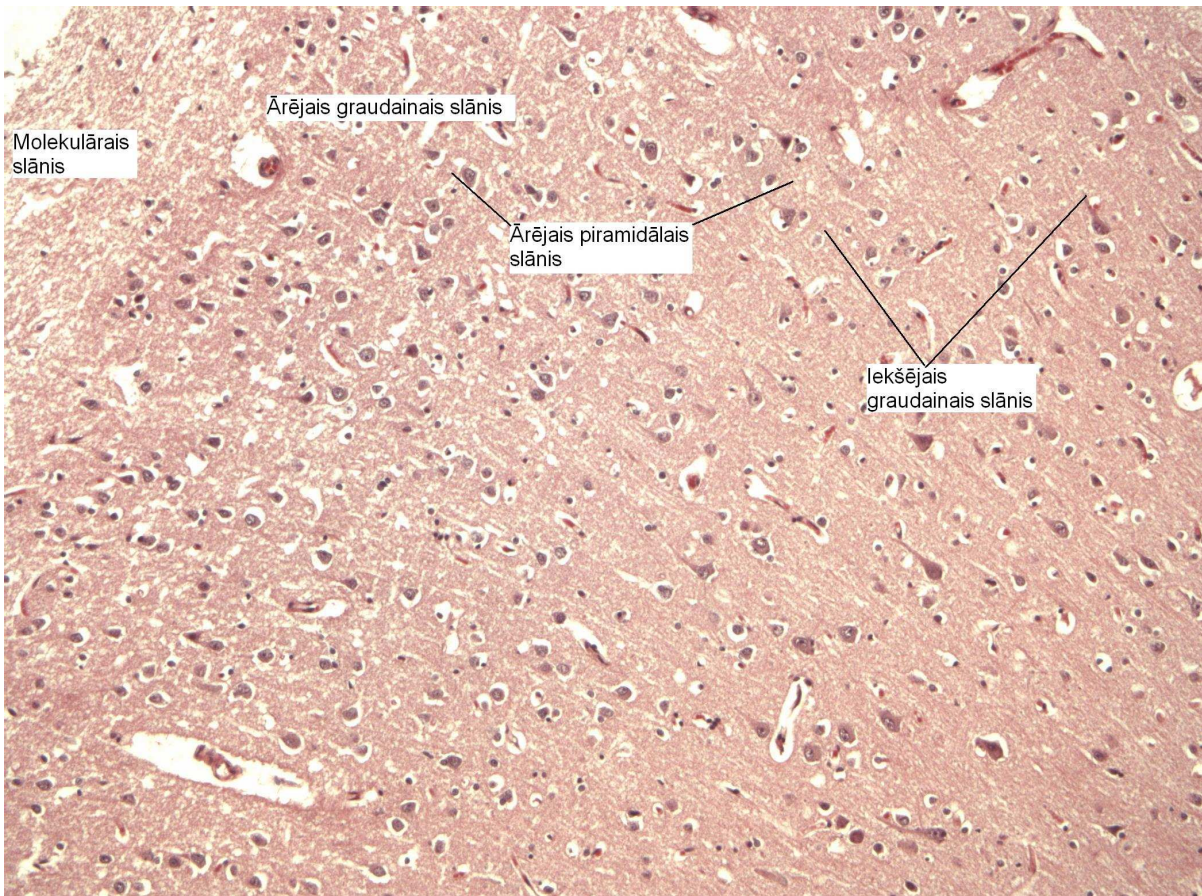


5. Pusložu garoza (sudrabs).

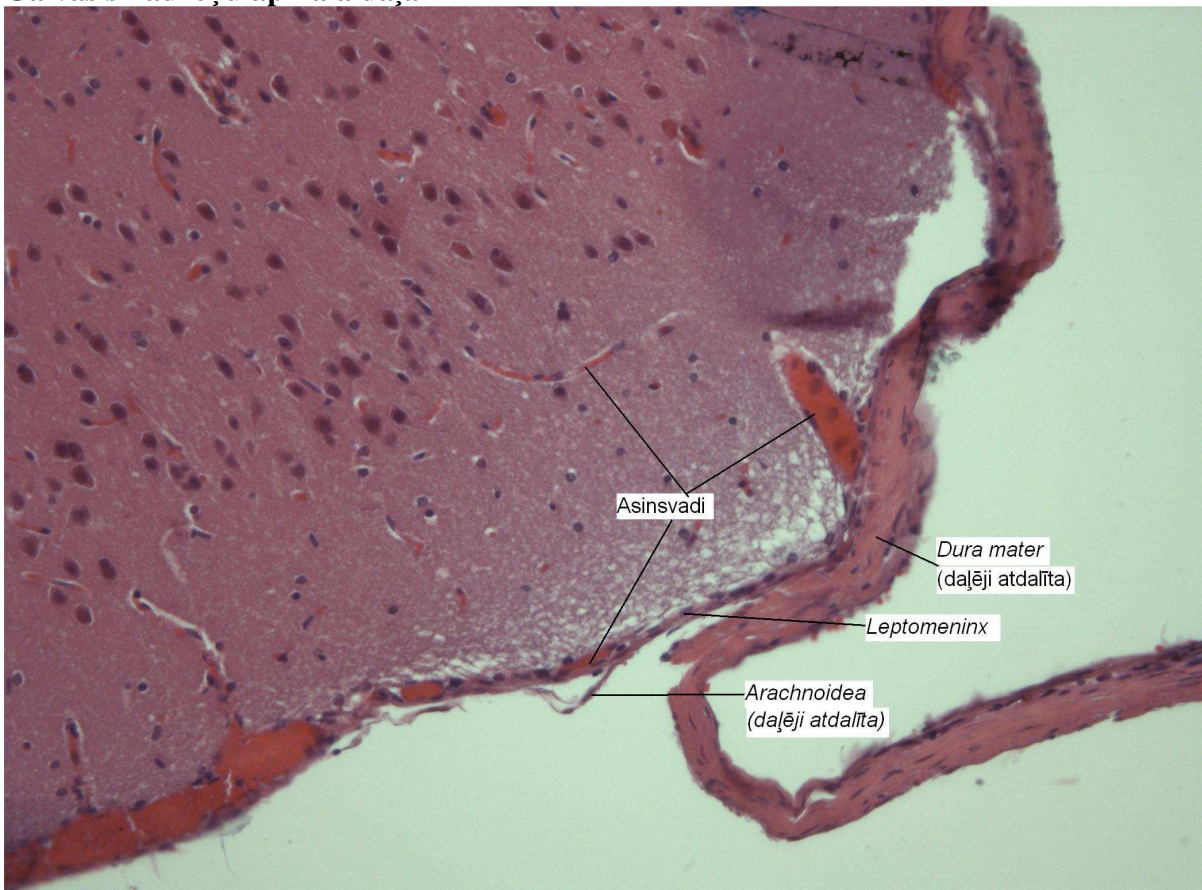


6. Pusložu garoza (H&E).

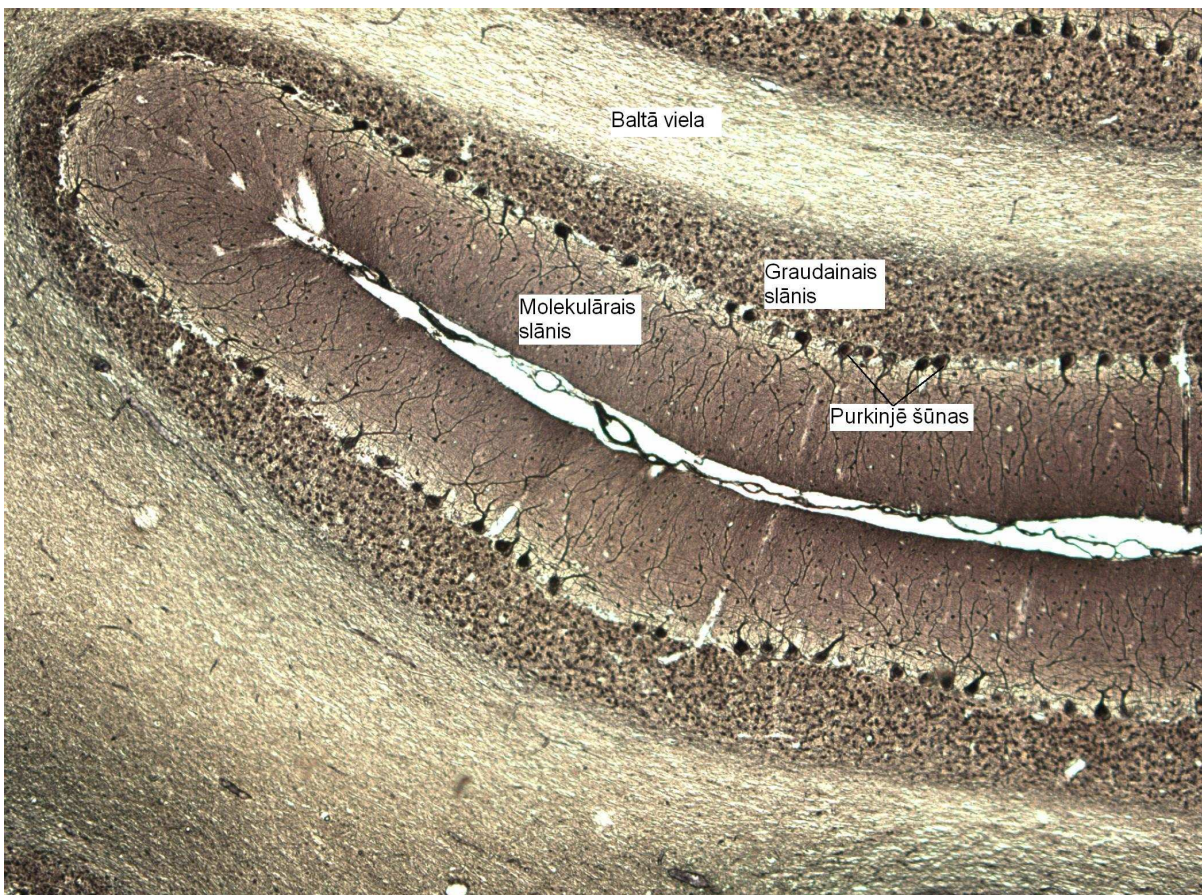
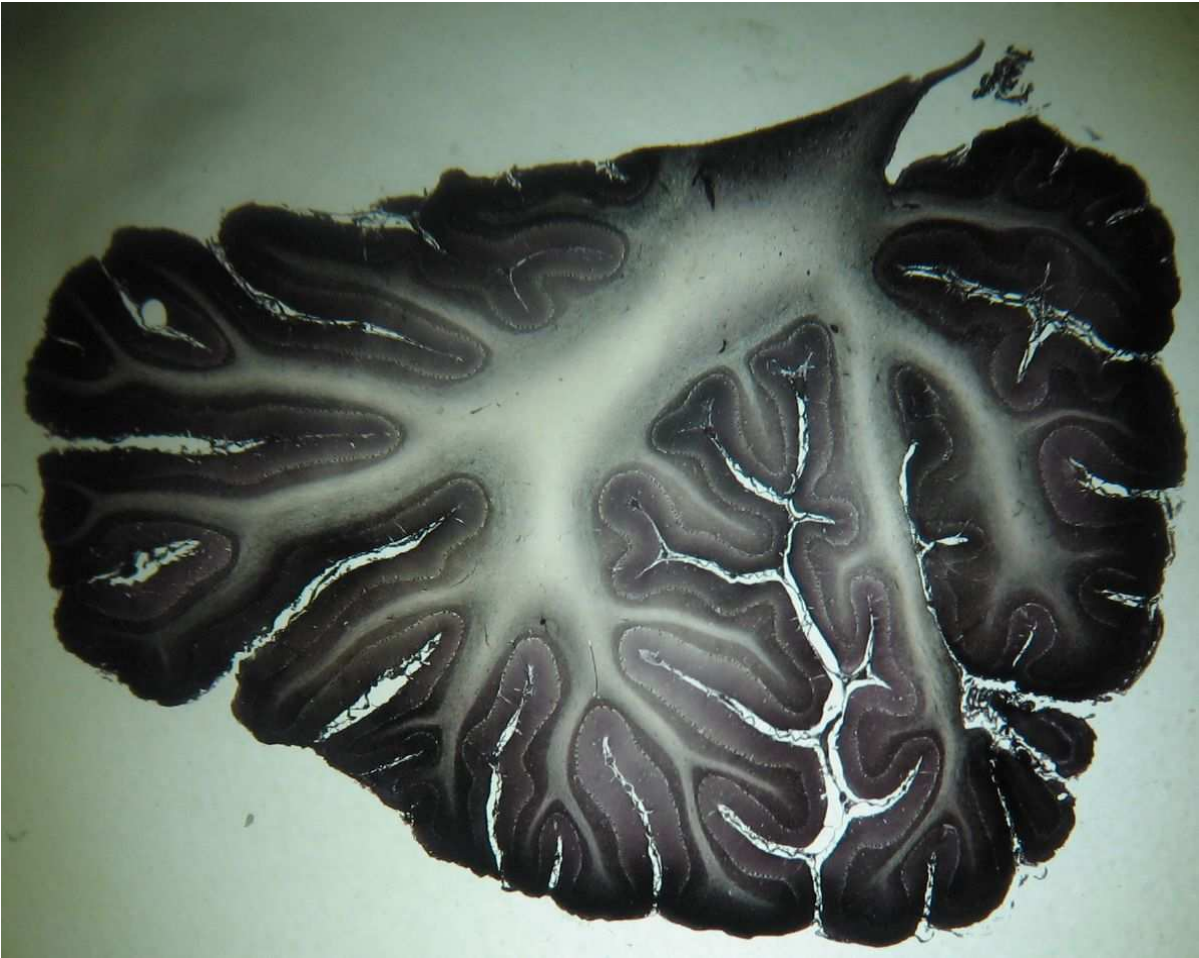




Galvas smadzeņu apikālā daļa

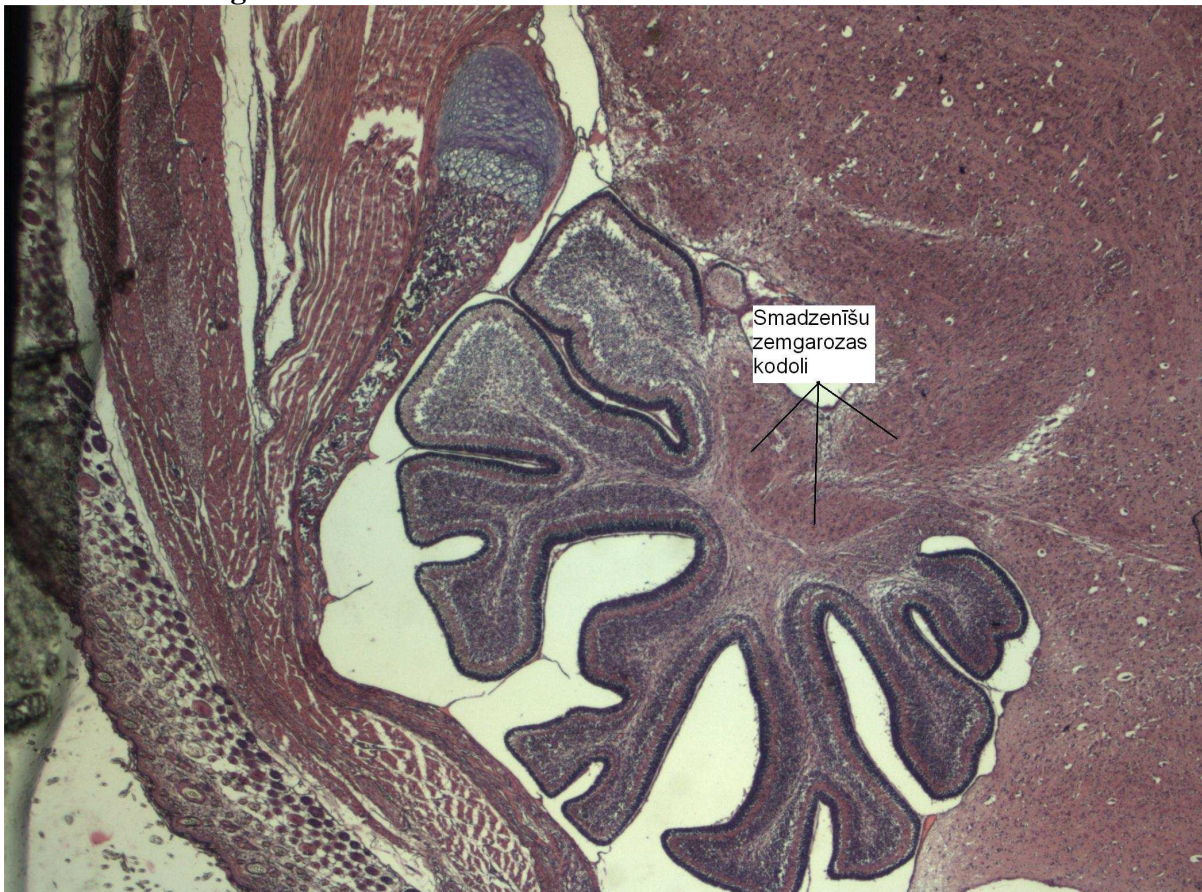

7. Smadzenītes.

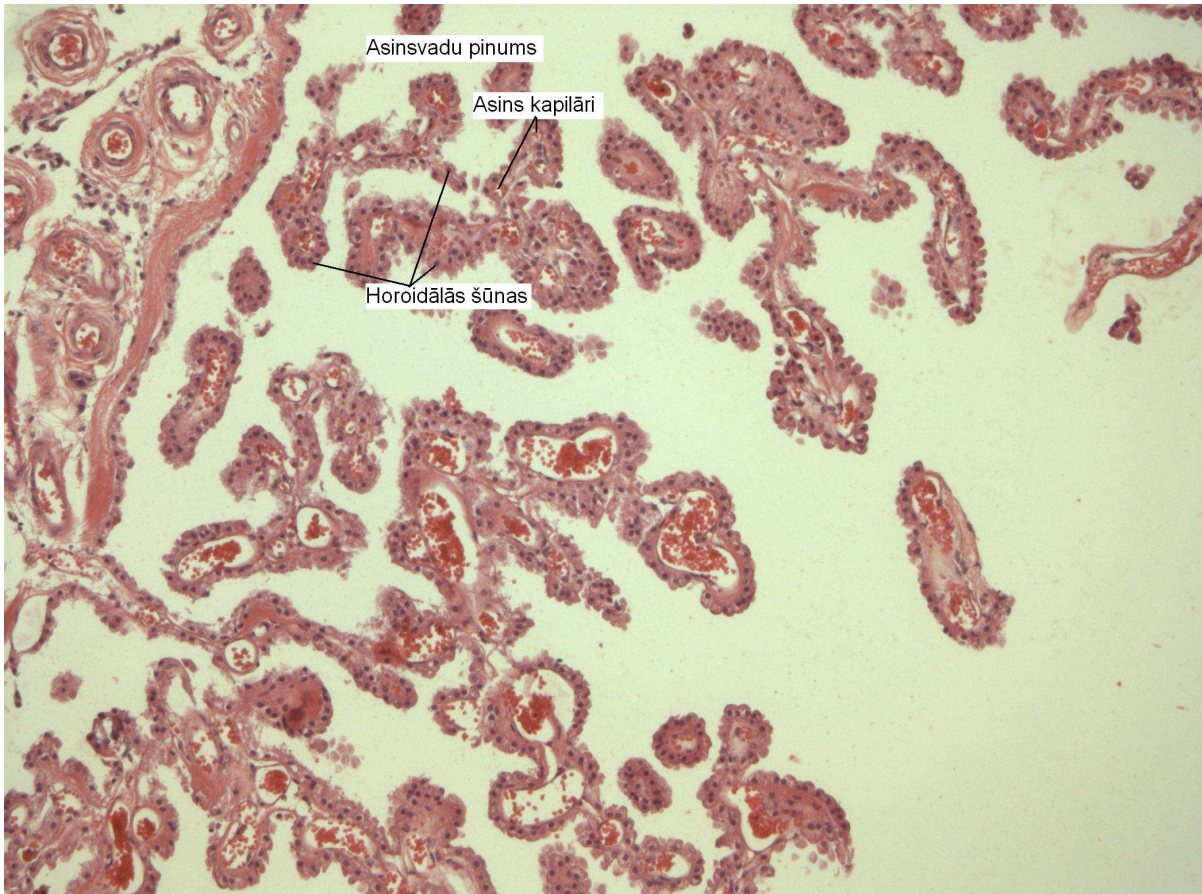




Smadzeņu zemgarozas kodoli.



8. Plexus chorioidens.



9. Lielo pusložu garozas mikrokolonnas.

