

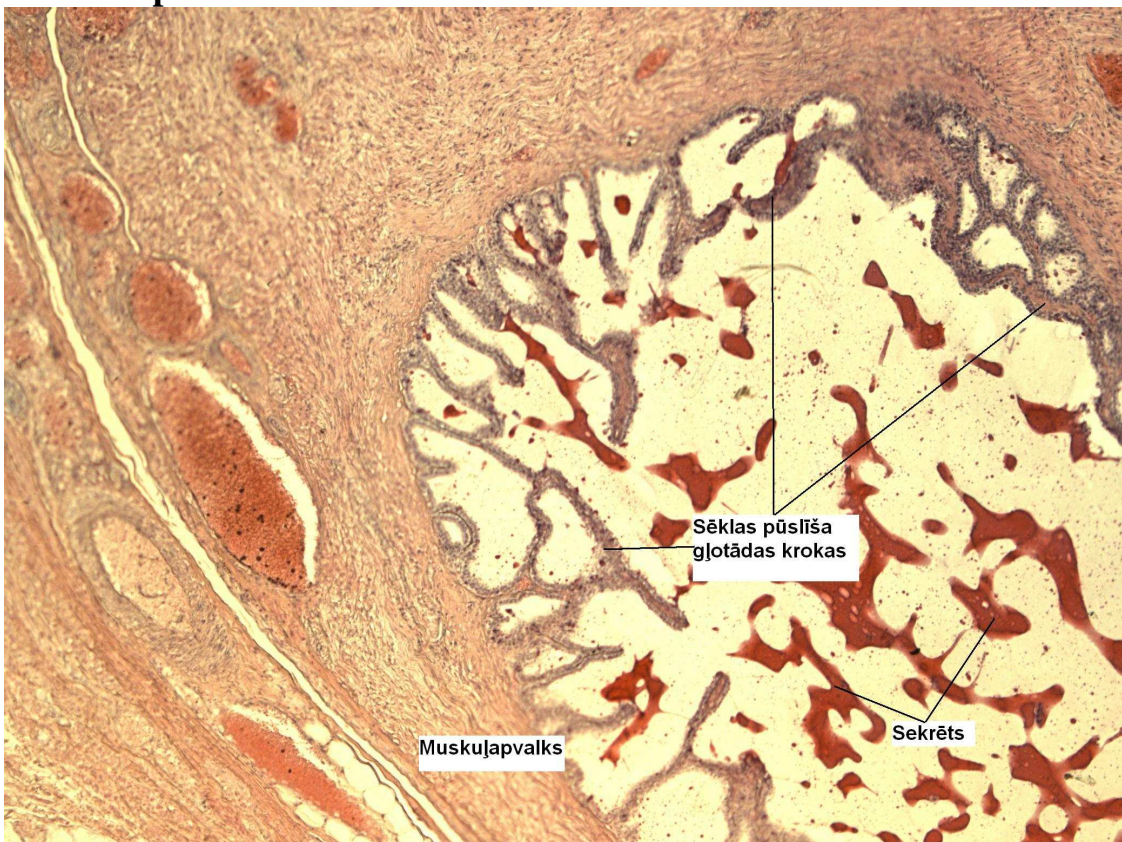
Speciālās histoloģijas kurss

Laboratorijas darbos izmantoto preparātu attēlu atlants

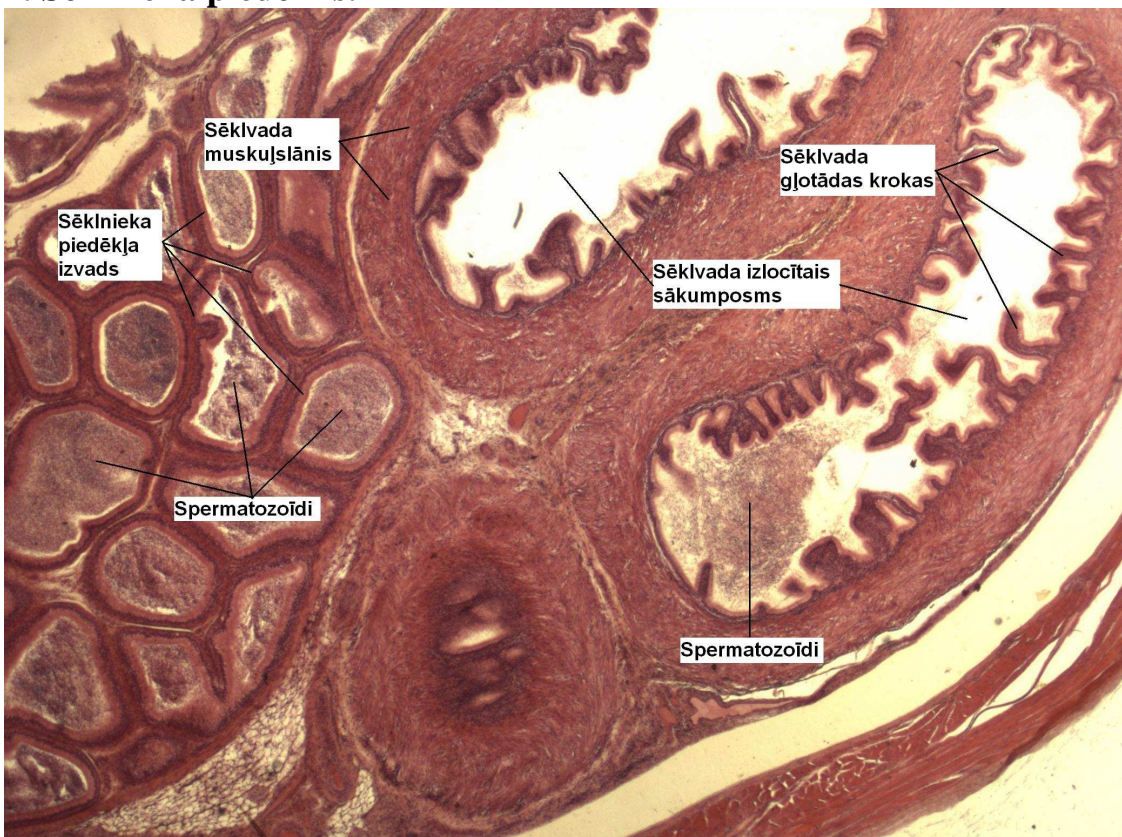Rīga 2011.

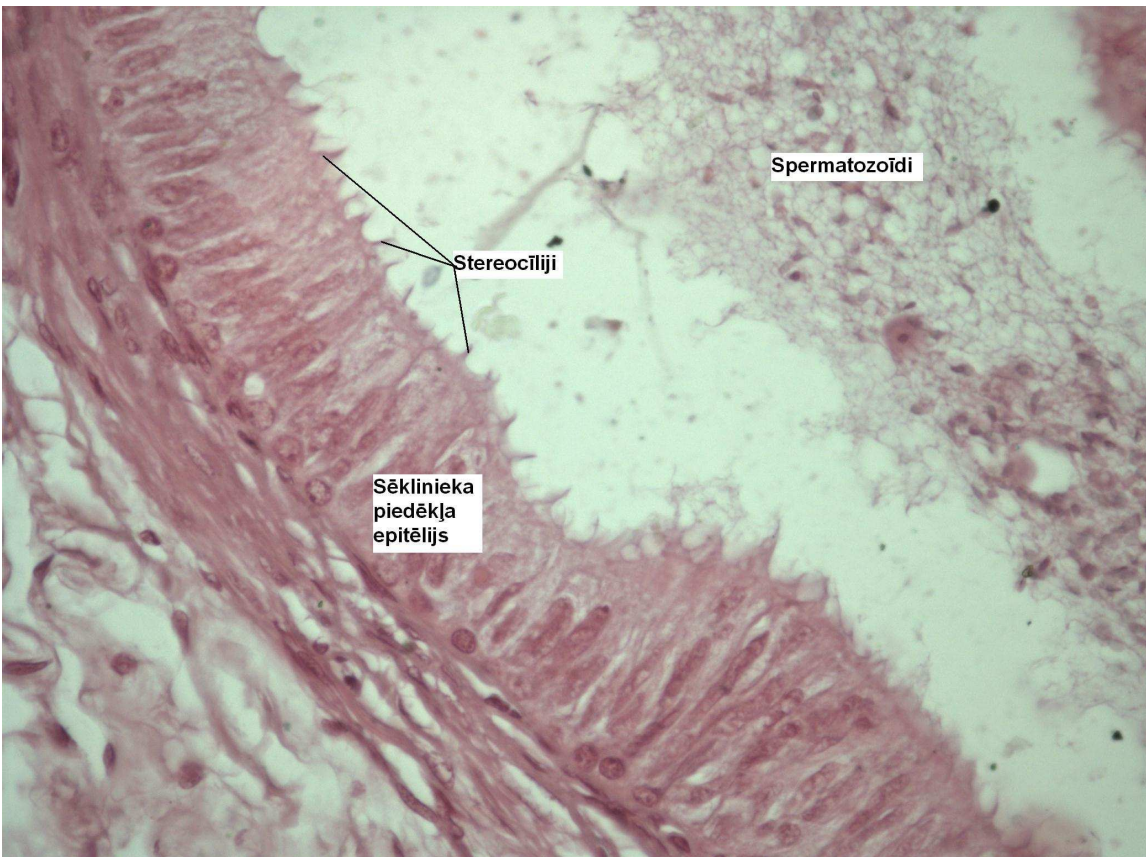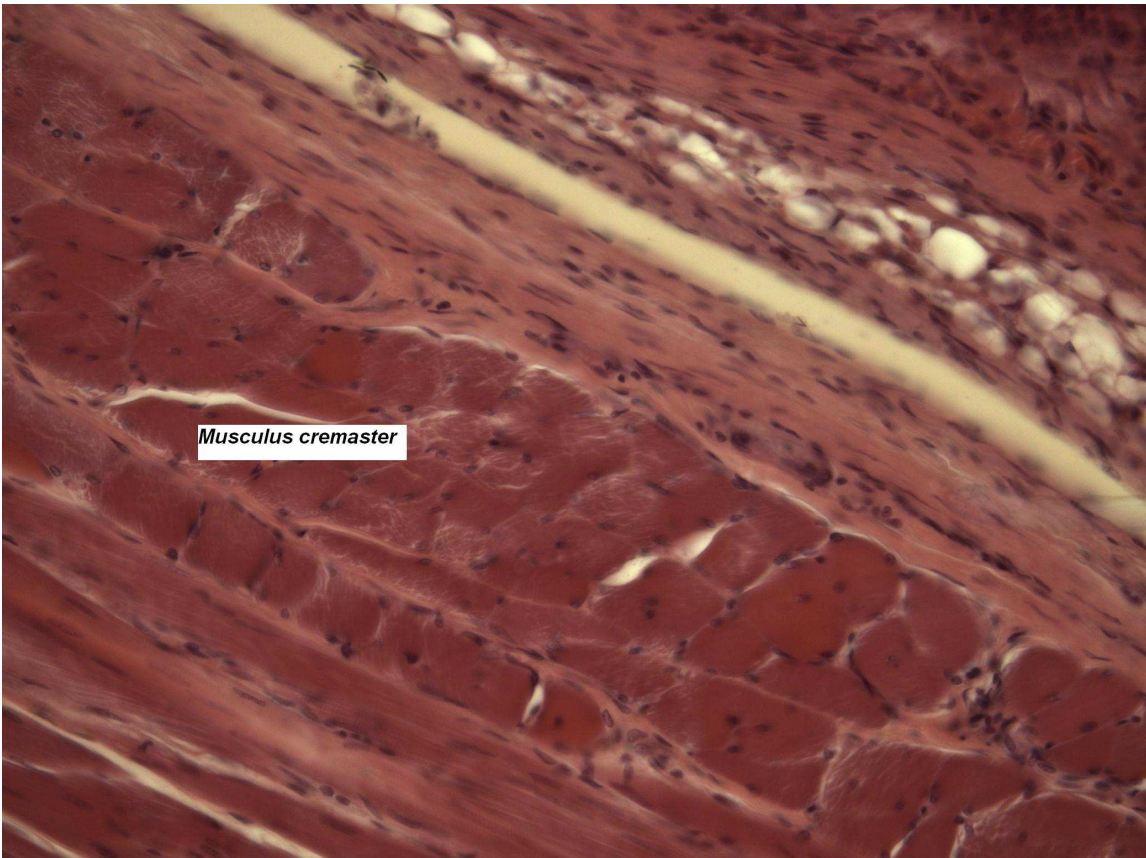
14. nodarbība Vīrieša dzimumsistēma

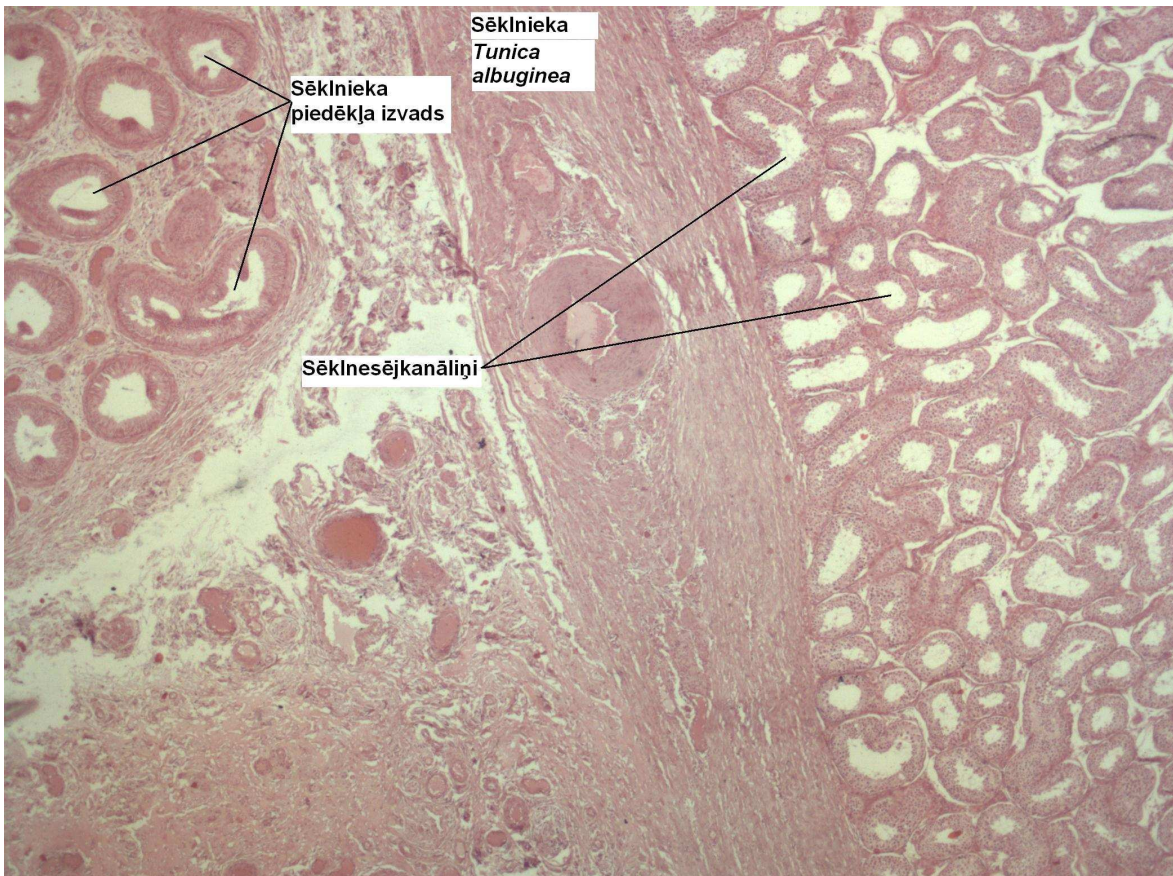
1. Sēklas pūslītis.



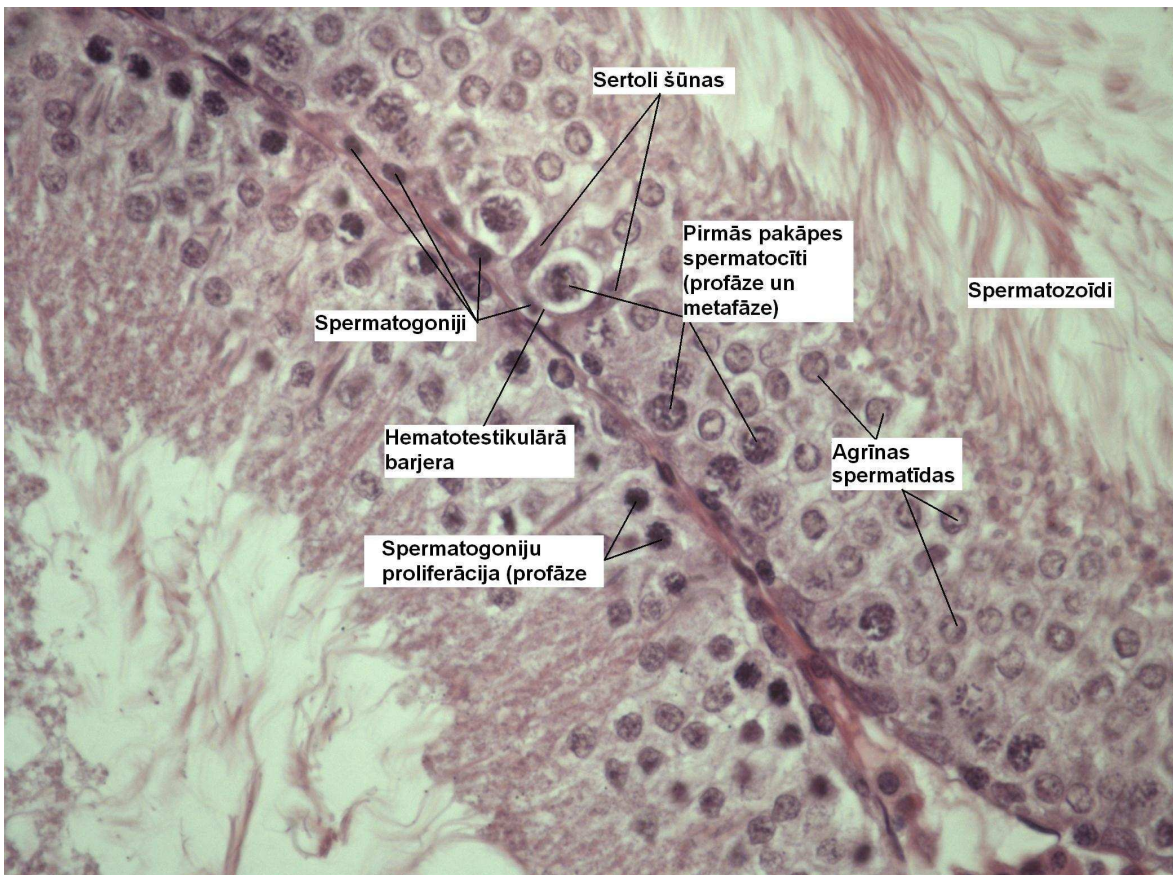
2. Sēklnieka piedēklis.

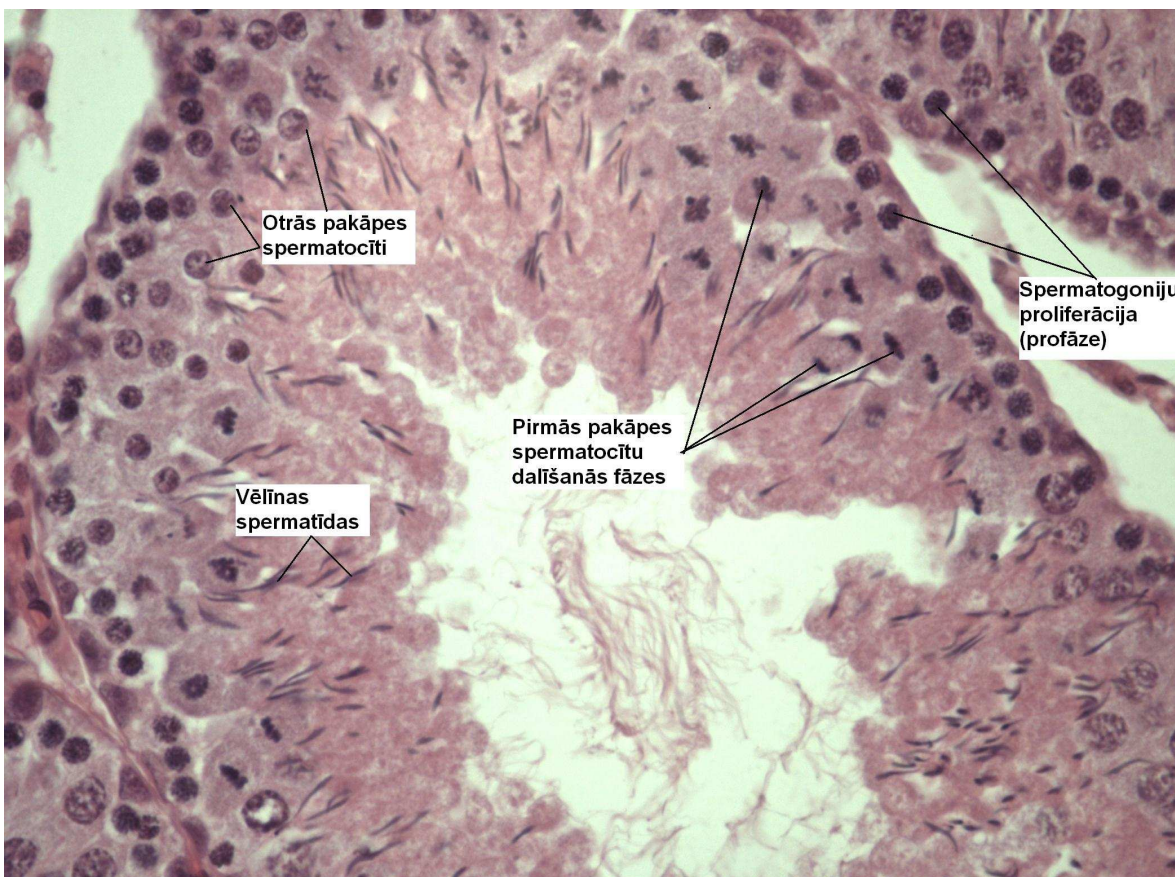
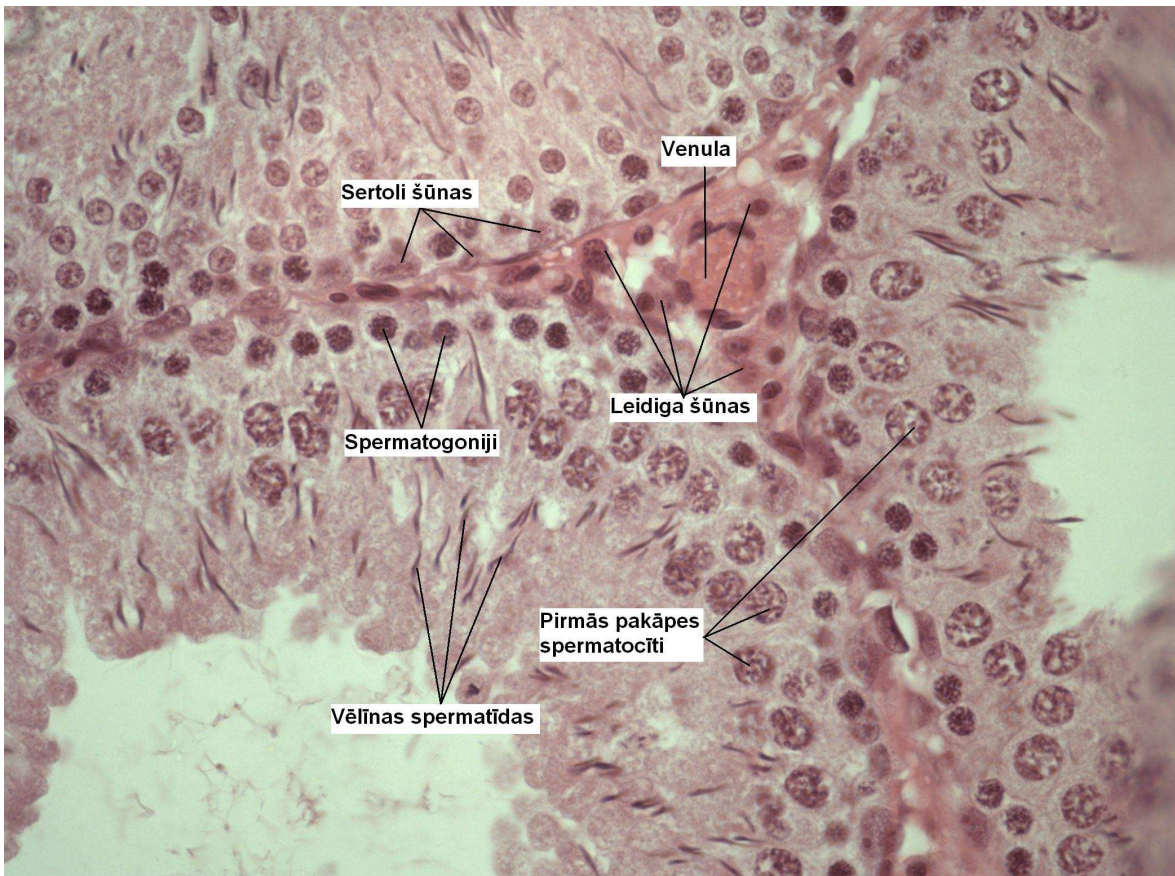



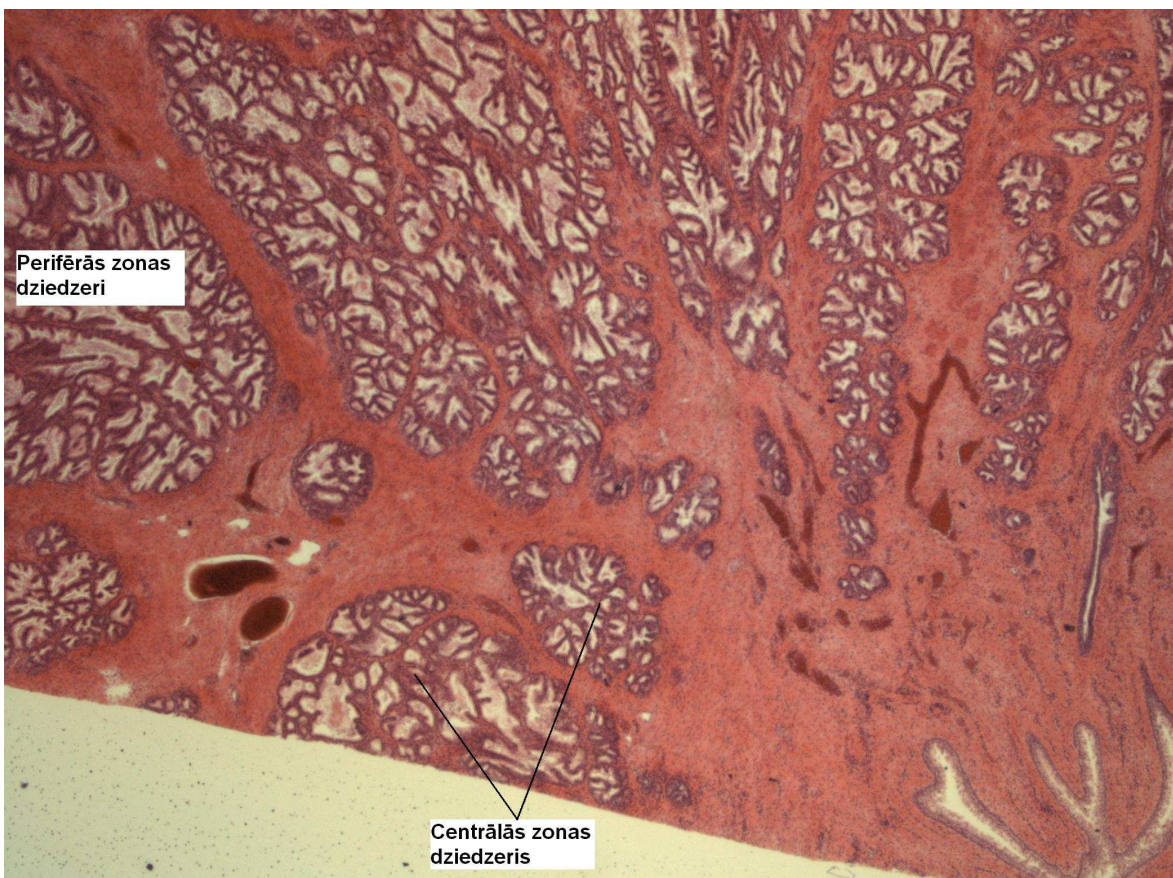

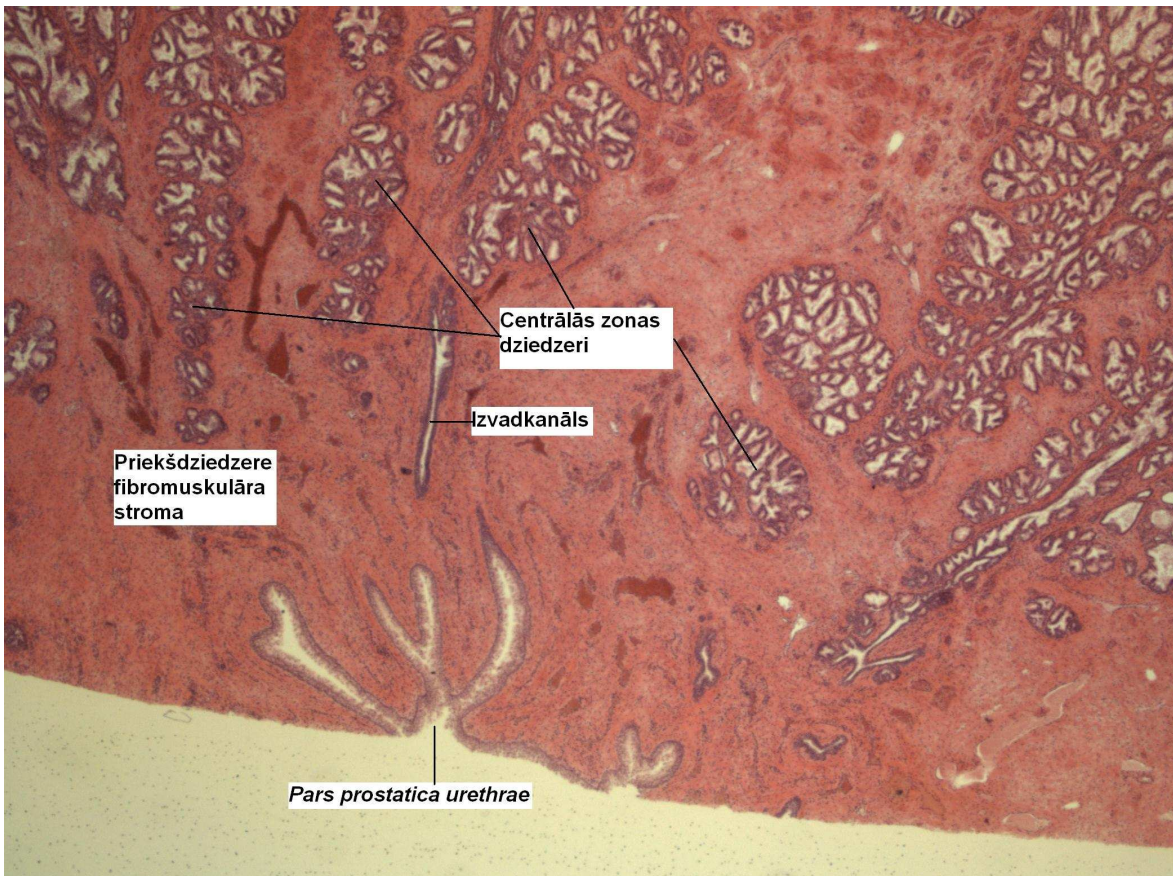
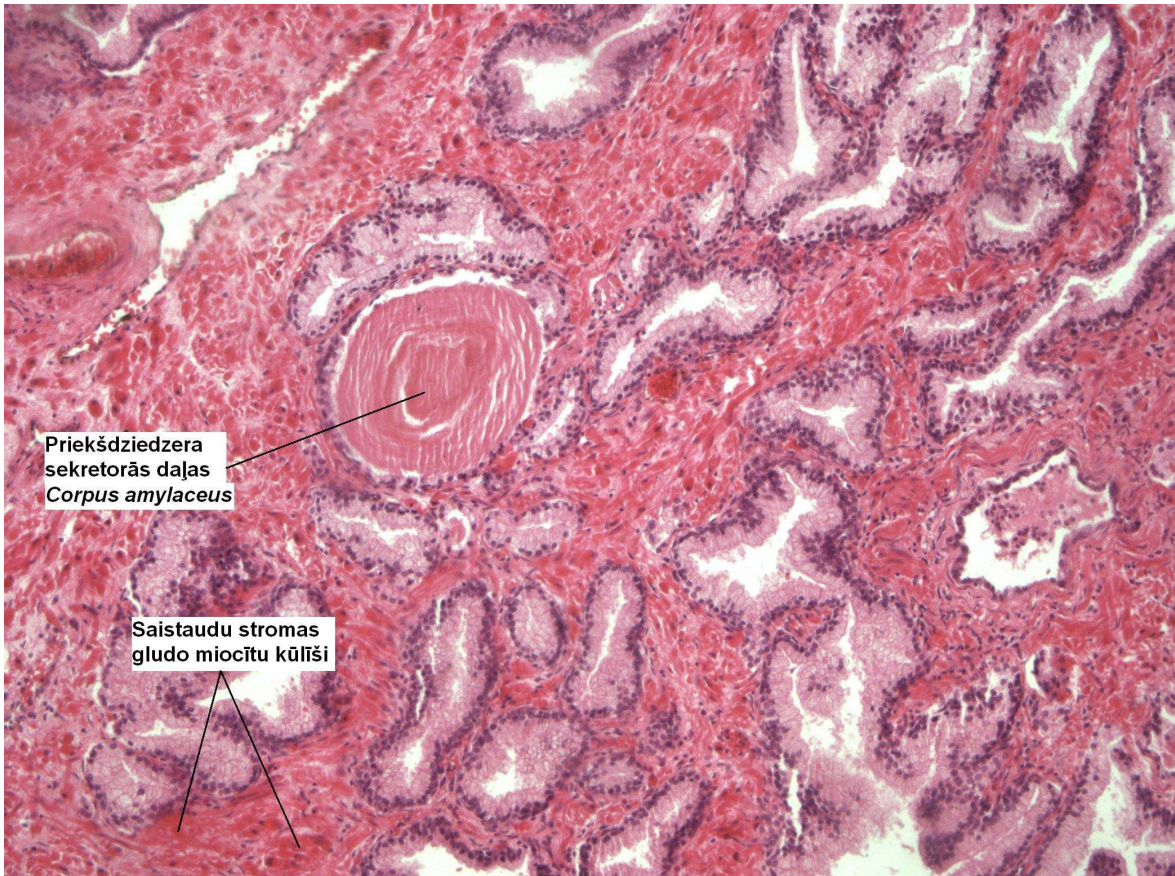
3. Sēklinieka mikrostruktūra



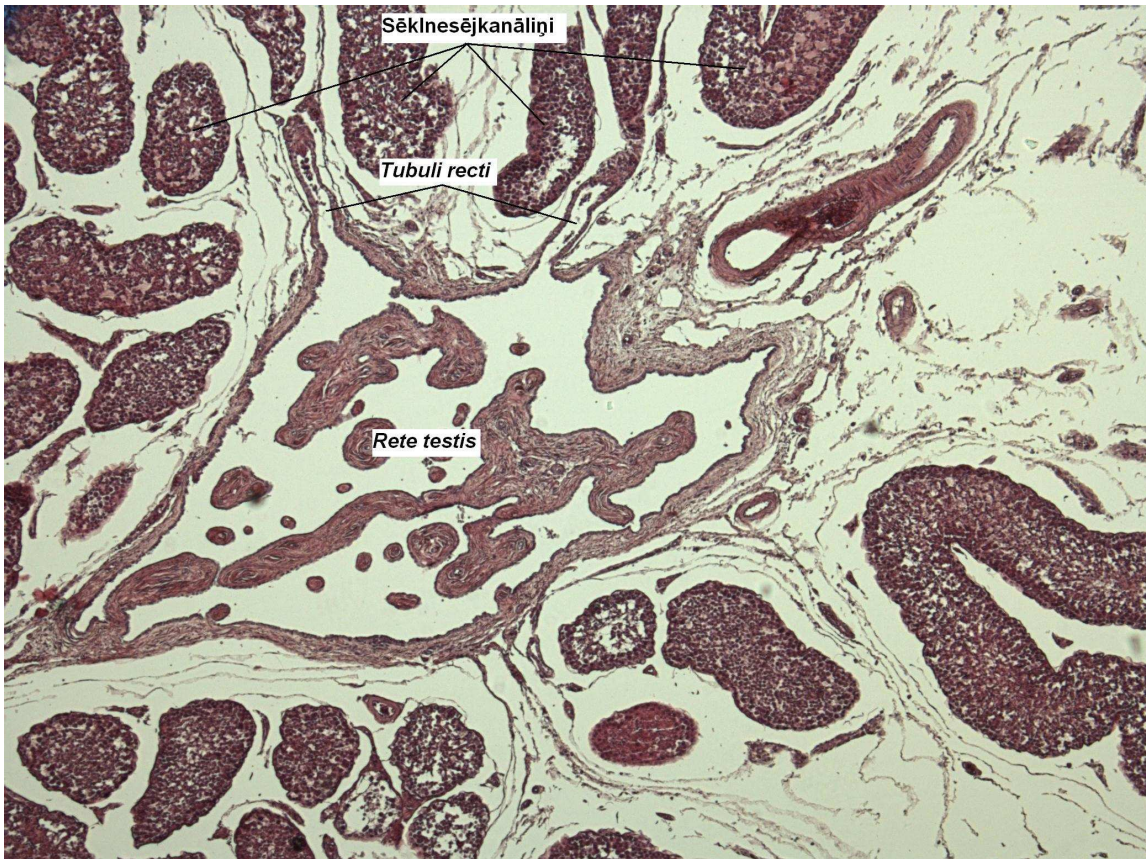


4. Priekšdziedzeris.

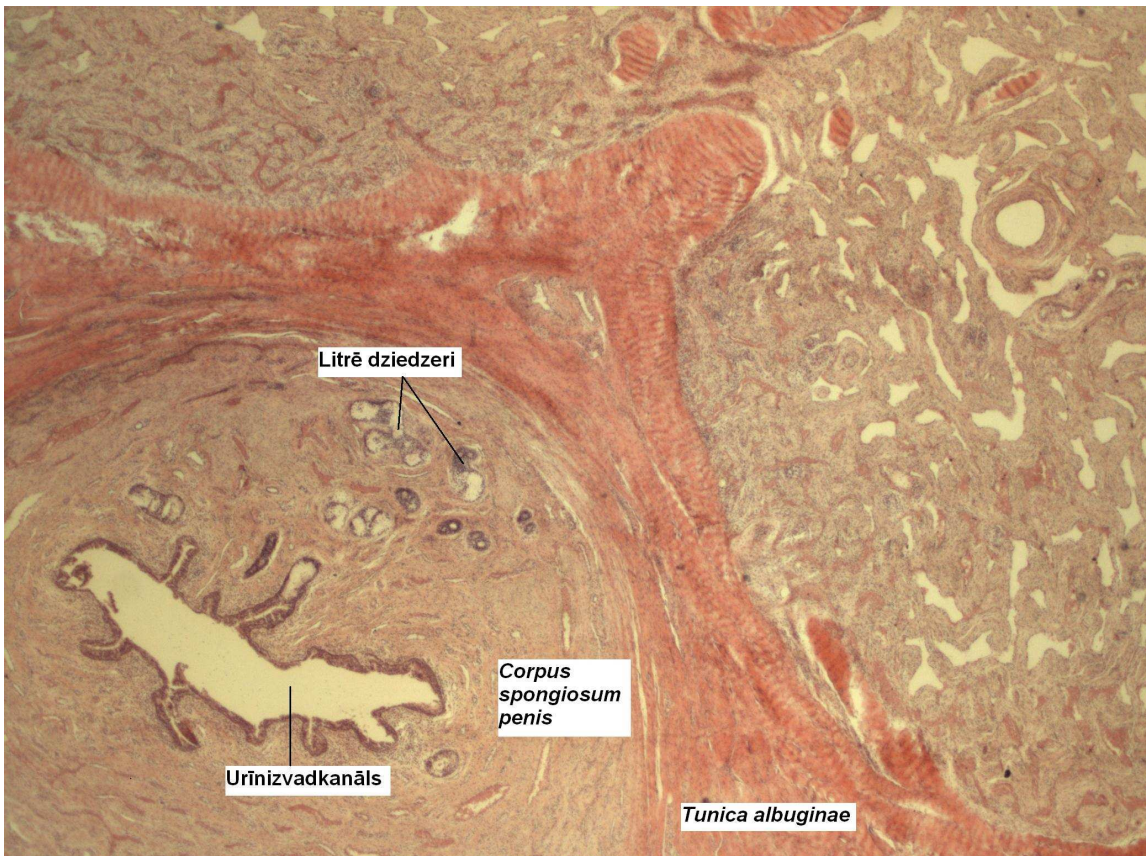


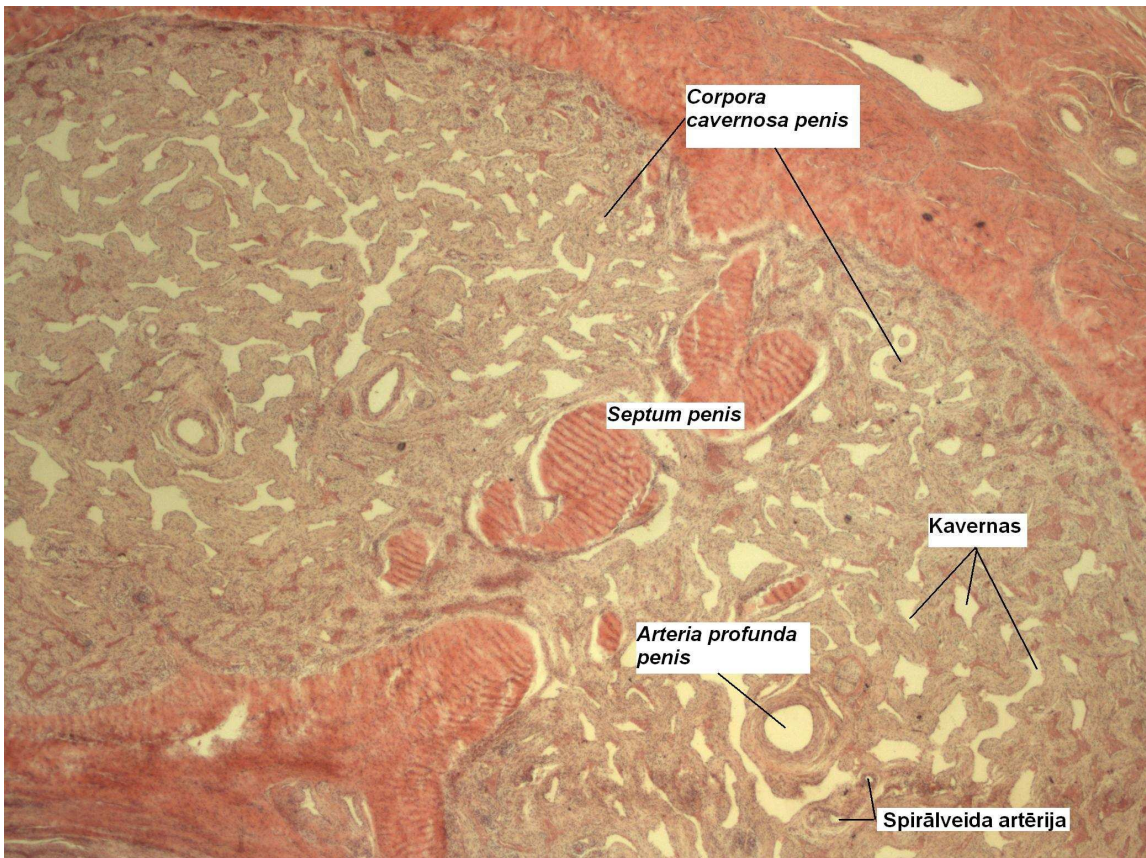


5. *Tubuli recti.*



6. Dzimumloceklis.





7. Spermatozoīdi.

