

Speciālās histoloģijas kurss

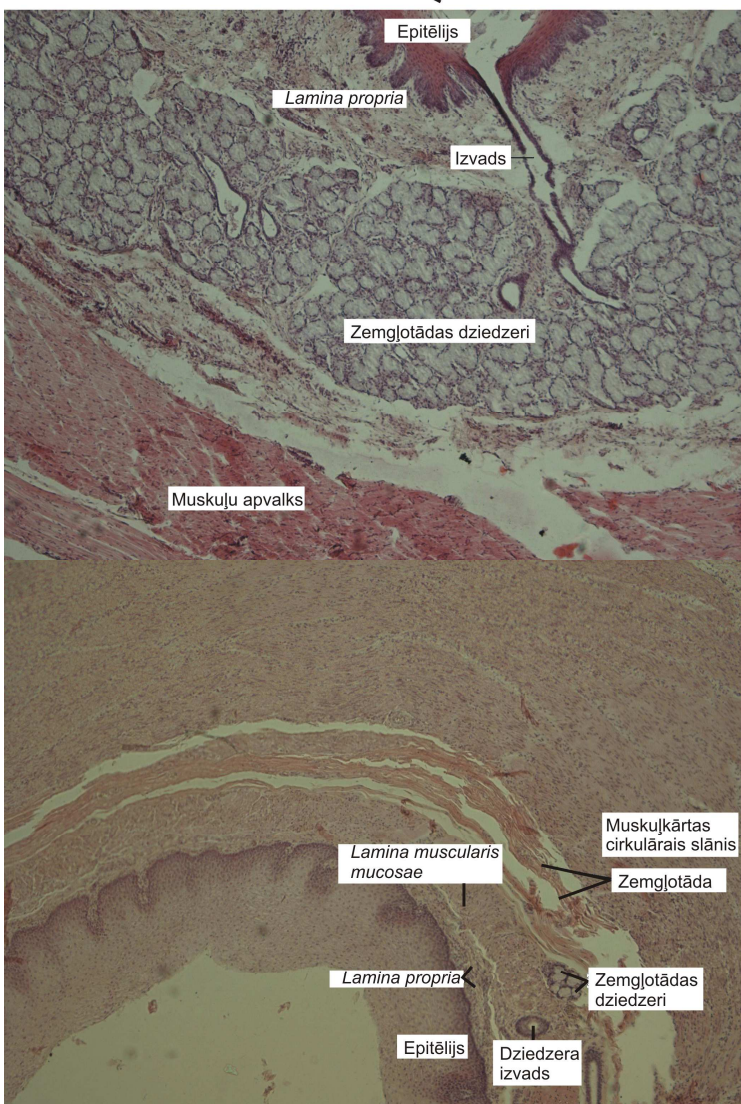
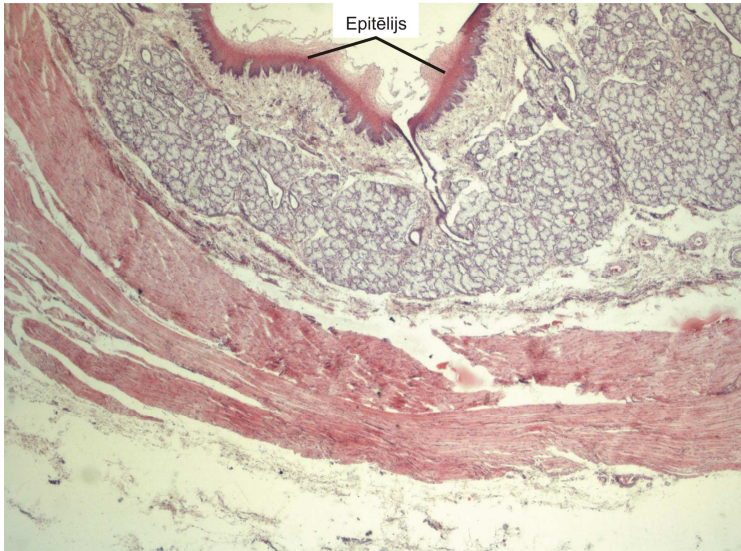
Laboratorijas darbos izmantoto preparātu attēlu atlants

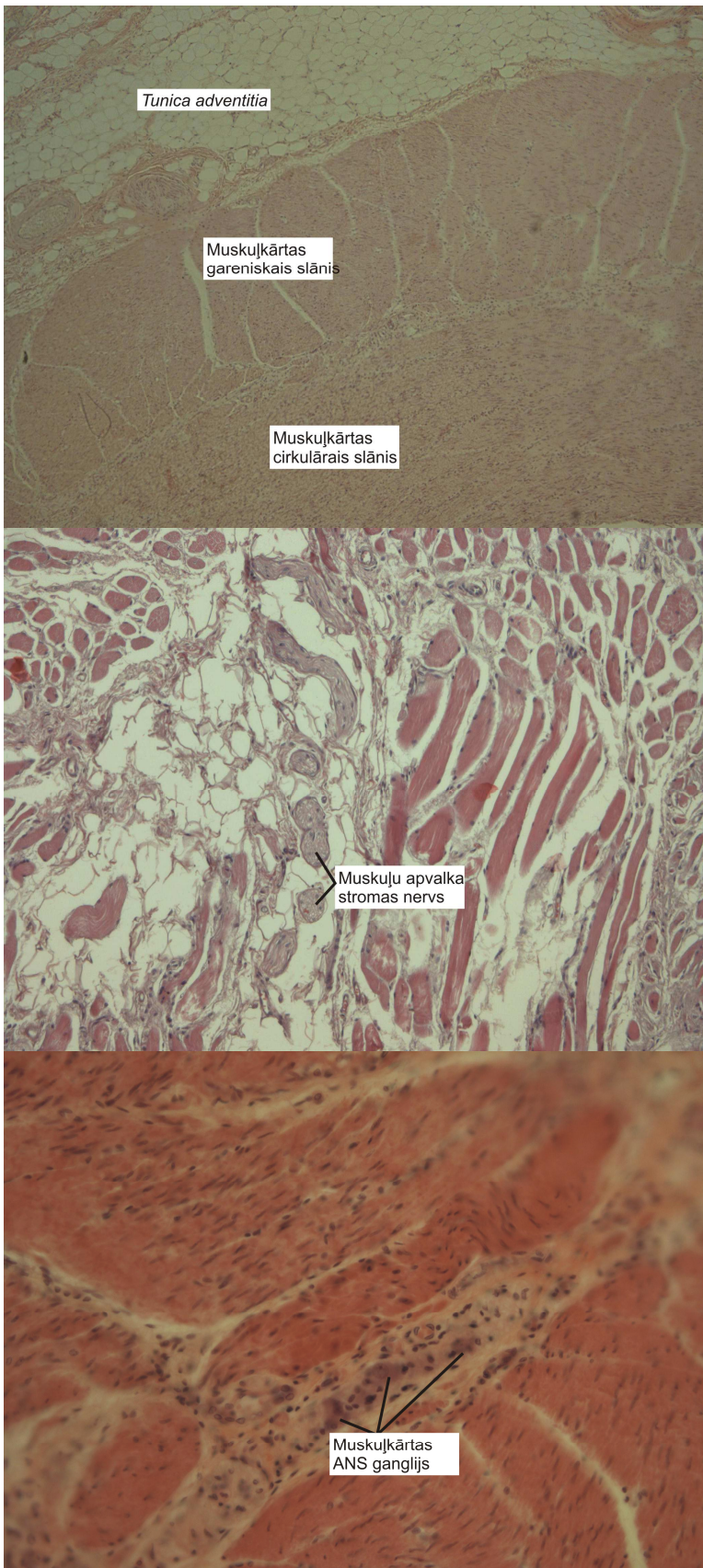
Rīga 2011.

3. nodarbība

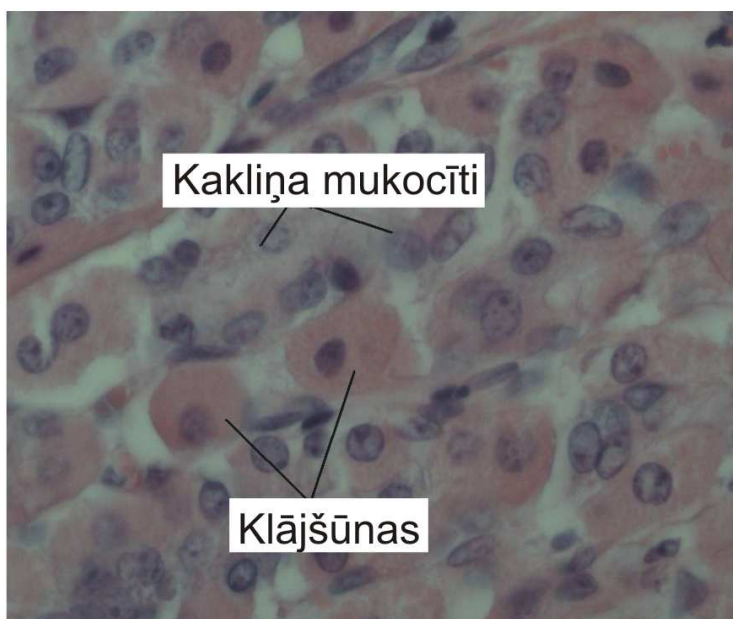
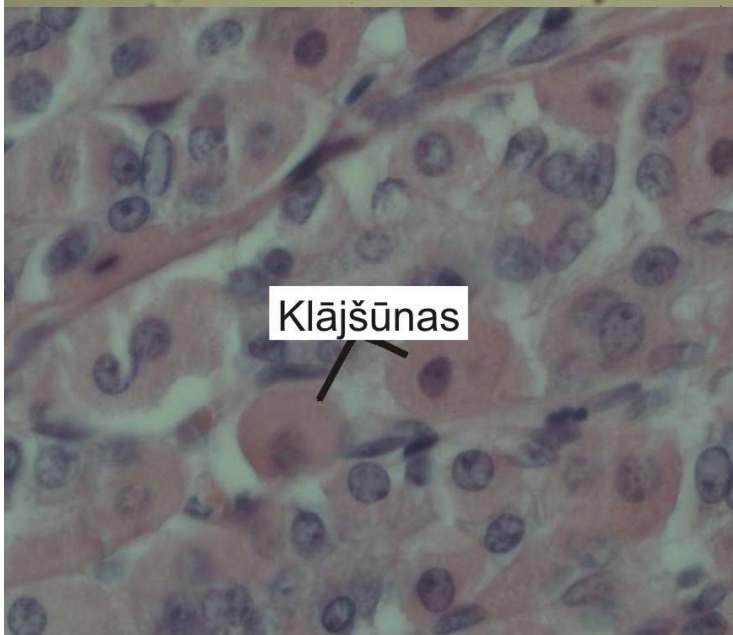
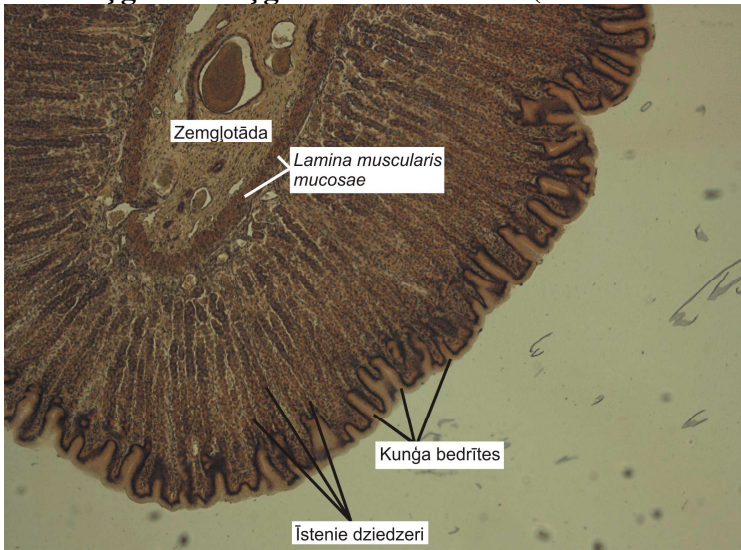Barības vads. Kuņģis. Tievā zarna. Tārpveida piedēklis. Resnā zarna.

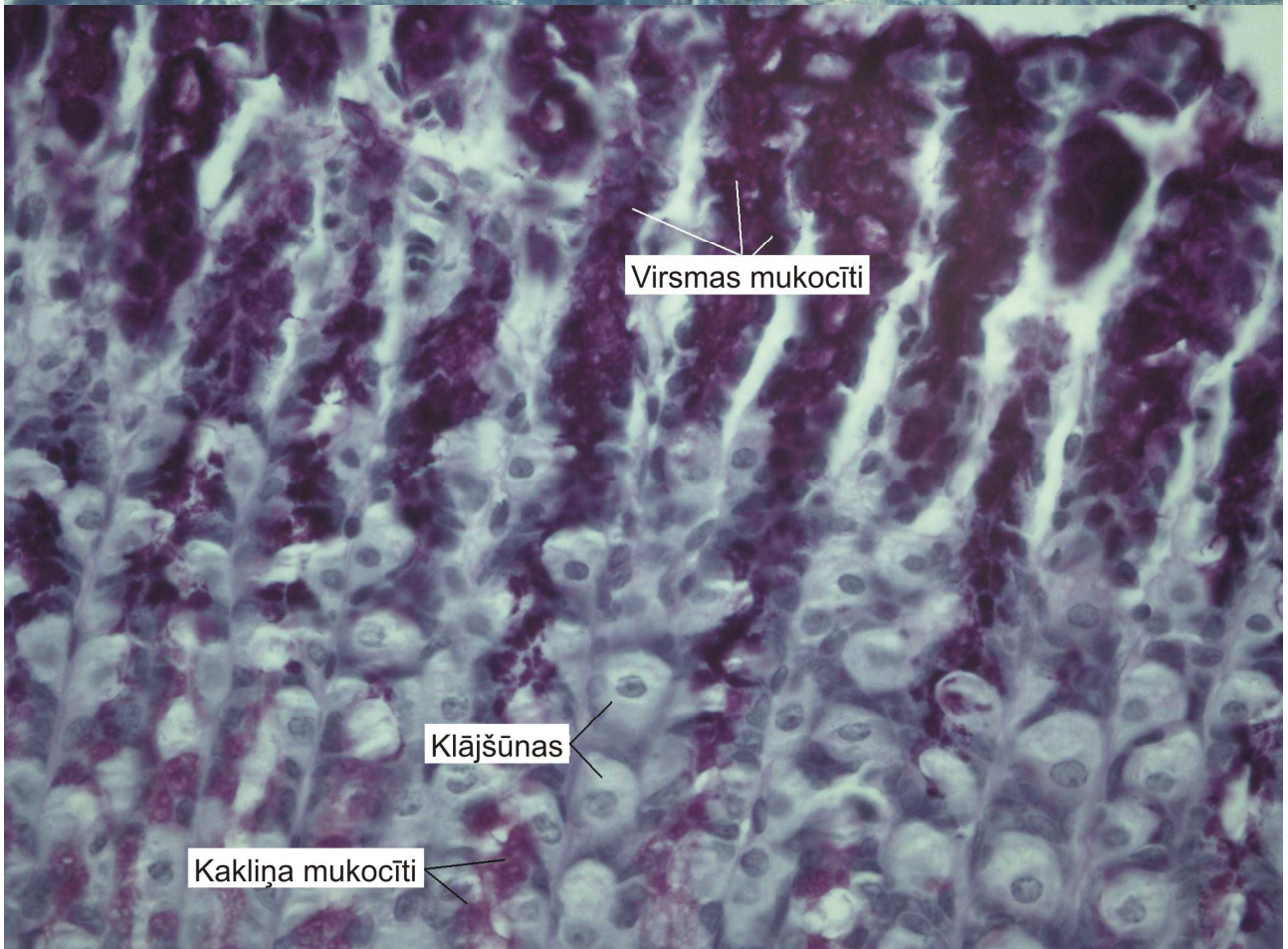
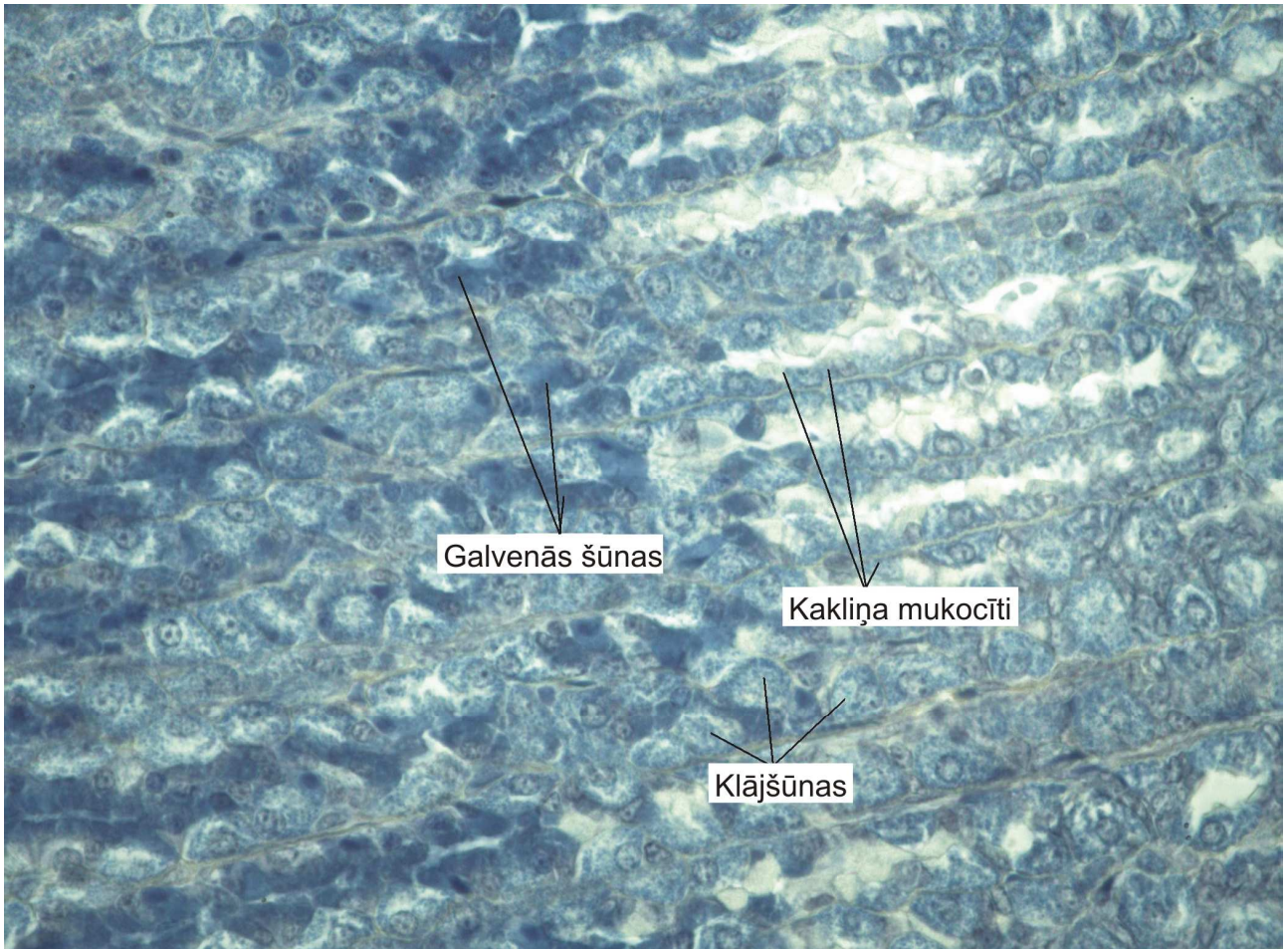
1. – Barības vads



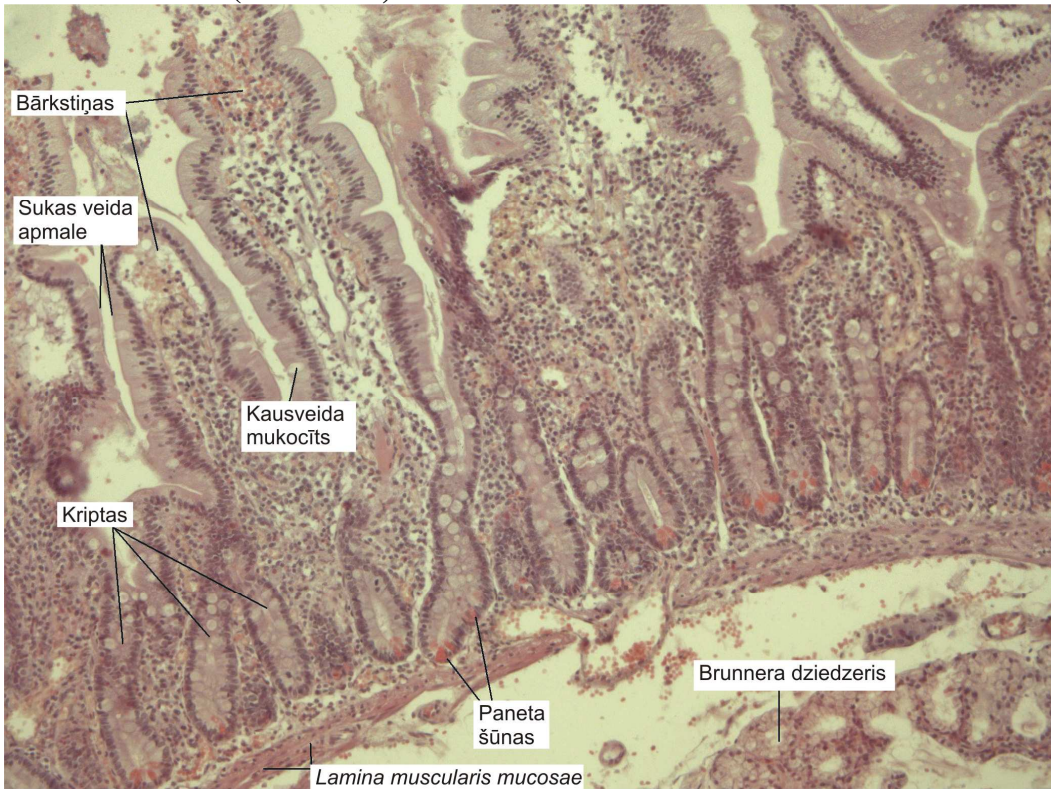


2. – Kuņģis un kuņģa īstenie dziedzeri (*Fundus ventriculi*).

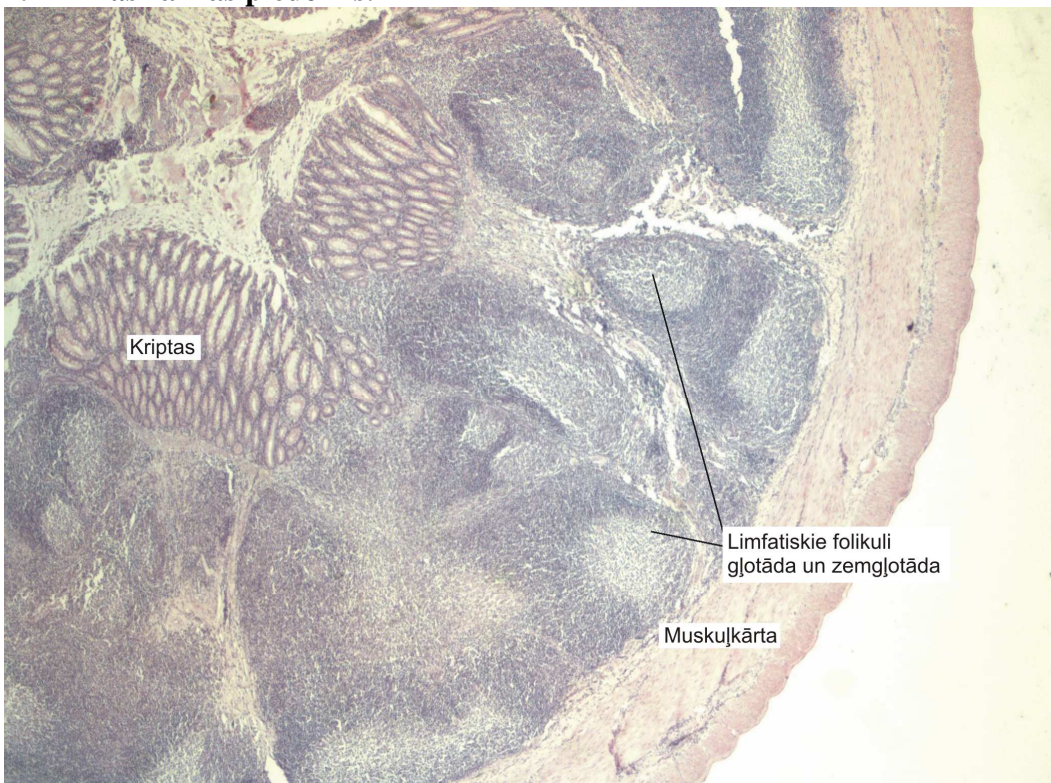




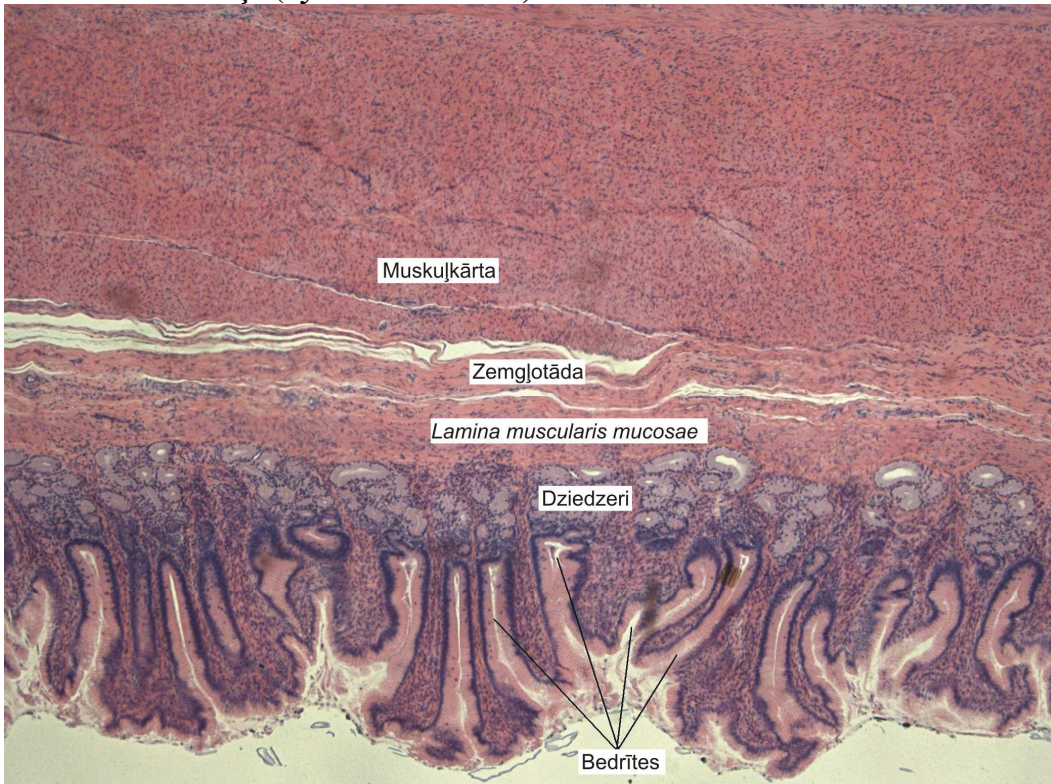
3. – Tievā zarna (*duodenum*)



4. – Aklās zarnas piedēklis.



5. – Vārtnieka daļa (*Pylorus-ventriculi*).



6. – Resnā zarna.

